



Original Article

ISSN : 2277-3657  
CODEN(USA) : IJPRPM

## ***Peculiarities of Pre-Peritoneal Hernioplasty in Surgical Treatment of Ventral Hernias of Lower and Median Localization***

**Dubchenko Volodymyr Serhiyovych<sup>1\*</sup>, Kryshen Valerii Pavlovych<sup>2</sup>**

<sup>1</sup>Department of General Surgery, Dnipro State Medical University State Institution “Specialized multidisciplinary hospital № 1 of the Ministry of Health of Ukraine”, Dnipro, Ukraine.

<sup>2</sup>Department of General Surgery, Dnipro State Medical University, Dnipro, Ukraine.

\*Email: [Dubchenko12@i.ua](mailto:Dubchenko12@i.ua)

---

### **ABSTRACT**

*The purpose of this research work is to analyze and substantiate the advantages of the laparoscopic hernioplasty method, its improvement, to improve the results of surgical treatment of hernias of medial and lower localization. In the process of this research, we used a comparison method based on the surgical intervention by TAPP and SUBLAY performed on 405 patients. Patients were questioned according to the SF-36 form to assess their physical and psychoemotional state before surgical intervention and in the remote postoperative period. Significant advantages of using preperitoneal laparoscopic hernioplasty over open preaponeurotic hernioplasty include low complication rates (9.24% and 11.25%, respectively), easier nature of complications, shorter hospital stay, and quicker return to habitual activities. Treatment of patients by the TAPP method compares favorably with the SUBLAY method due to a smaller number of early and late complications, the nature and severity of complications, complications are easier to correct, the period of hospitalization is shorter, and the rehabilitation period is shorter. Laparoscopic technique for the treatment of hernias of medium and lower localization has a large number of supporters, both in Ukraine and in the world, who believe that the main advantage of this technique is the absence of contact with the free abdominal cavity and no reason for the formation of adhesions of the abdominal cavity organs, and therefore significantly reduced the risk of intra- and postoperative complications. Thus, the development and implementation of laparoscopic techniques show significant advantages in comparison with open laparotomy methods.*

**Key words:** *Laparoscopic hernioplasty, Ventral hernia, Postoperative hernia, Recurrence, Umbilical hernia, Open preaponeurotic plastics*

---

### **INTRODUCTION**

Abdominal hernias are one of the most common surgical pathologies, affecting about 3-4% of the world's population each year. The highest frequency of this problem occurs in children of preschool age, the able-bodied population, as well as in patients after 50 years of age. Groin hernias are the most common among men, and umbilical hernias are common among women. The prevalence of ventral postoperative hernias is almost the same for both men and women. According to the WHO, the incidence of ventral hernia averages 4-7% in the world [1]. About 100 thousand hernia surgeries are performed annually in Ukraine, more than 300 thousand surgeries are performed annually in the USA; in the world, this figure is about 20 million [2]. Clinically, abdominal hernias are accompanied by different symptoms: pain, dyspepsia, limitation of physical activity. The intensity of the symptoms depends on the size of the hernial bulge, its localization, the duration of the hernia, the nature of the contents of the hernia sac<sup>3</sup>. The issue of anterior abdominal wall reconstruction in patients with ventral hernias of lower and median localization has been a hot topic for many years. The main paradigm in

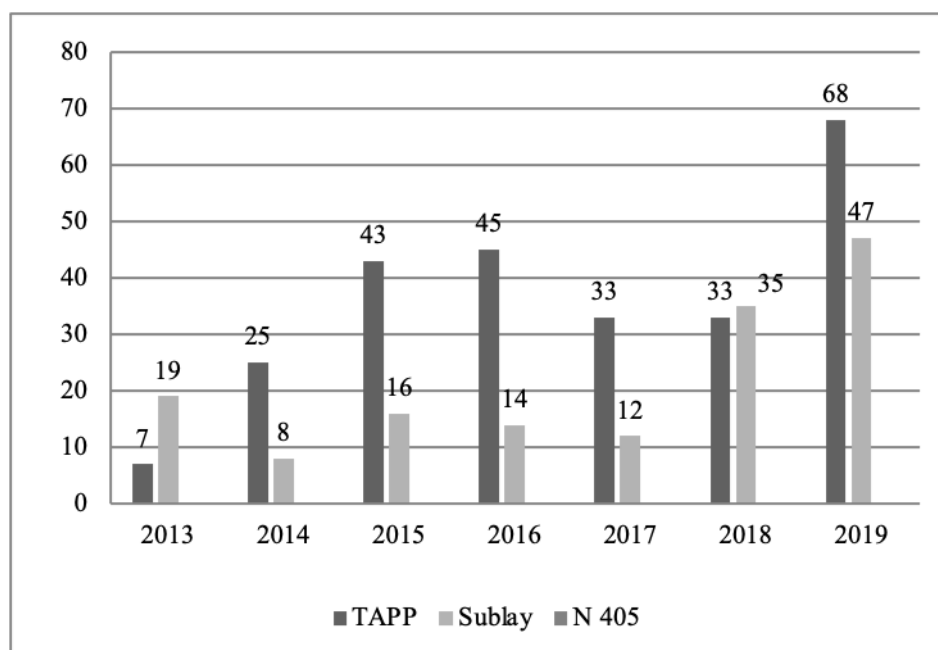
their treatment is to achieve the maximum result of the healing process through the use of the least invasive operations. The problem of effective treatment of abdominal hernias remains extremely important because this pathology is common among the able-bodied population. It is known that when performing "open" type operations in patients with umbilical, inguinal, postoperative hernia there is often a high risk of recurrence and complications: the presence of chronic abdominal pain, adhesions. Traditional techniques of surgical treatment of hernias of medium and lower localization are accompanied by significant trauma of soft tissues, which leads to severe pain and disability for up to 1-2 months. The time of hospitalization is no less important because the recovery and rehabilitation period during open surgery takes much longer and requires significant financial losses [1]. The surgical treatment and rehabilitation period require significant material resources among the patients. For example, in the United States, the total cost of hernia treatment is estimated to be about \$320,000,000 per year [3]. Ventral hernias of moderate and inferior localization are a frequent pathology and can be associated with life-threatening complications for the patient's health and life [4, 5]. The mortality rate in elective surgery is relatively low (about 0.05%), but this rate increases significantly in the presence of large recurrent ventral and impingement hernias and reaches 10-20% [6]. This is especially true in older patients with concomitant cardiovascular and pulmonary pathology, obesity, and is also observed in late hospitalization [7-9]. Equally common are postoperative hernias (10.2%), which occur after surgical interventions on the abdominal organs. This is associated not only with postoperative infectious complications but also with the increasing number of factors that reduce the strength of the muscular-aponeurotic tissues of the abdominal wall, which include obesity, exhaustion, taking steroid drugs [10]. Herniology has been developing rapidly in recent years, by increasing the frequency of the use of reliable techniques while reducing the traumatic nature of the techniques used, the use of laparoscopy. According to Surgical Endoscopy and Other Interventional Techniques, a long-term multicenter study conducted in Germany, which compares laparoscopic hernioplasty with open surgery in patients with ventral hernias, is described<sup>9</sup>. The author proves that laparoscopic prosthetic ventral hernioplasty reduces the volume of the wound defect compared to the open method, is important in patients with comorbidities, and is safe, especially when the ePTFE mesh is used. Compared with conventional open hernioplasty, the laparoscopic technique can reduce the patient's hospitalization time, reduce the number of common postoperative complications as well as frequent complications (seroma development, infection), and facilitate a quicker return to routine activities [11, 12]. The use of self-adhesive nets during laparoscopic transabdominal preperitoneal approach for small and medium ventral hernias is safe and effective, with low postoperative pain, rapid functional recovery, and high overall satisfaction after surgery without increasing recurrence in the short term [13]. Significant advantages of a fully retroperitoneal laparoscopic hernioplasty over an open retroperitoneal approach include a lower rate of total postoperative complications, reduced urinary dysfunction, and earlier return to habitual activities [1]. Significant advantages of laparoscopic herniotomy are observed in patients with postoperative ventral abdominal wall hernia associated with obesity. Application of this method of surgical treatment not only eliminates aesthetic inconveniences but also promotes psychological and social rehabilitation, significantly improves the quality of life of patients, and provides a satisfactory cosmetic effect [14]. But some studies prove that open hernioplasty in some cases has the same positive results for patient health as the laparoscopic method. Such results were obtained in patients who previously underwent cholecystectomy and splenectomy [15]. Also, there are studies conducted on a retrospective review of patients who have undergone laparoscopic hernioplasty (by TAPP or Tep methods) on the example of the study of the main problems that lead to recurrence. These studies show that the recurrence rate after hernioplasty performed by experienced surgeons was extremely low, undesirable effects of surgery can be foreseen and corrected due to the experience of the surgeon, and a certain proportion of such cases, require replacement of the technique and equipment used during surgery [16]. As Trap R. (Surgeon, Doctor of Surgery and Gastroenterology, Grostrul Hospital, Denmark) notes in the scientific surgical publication Repair of Ventral Hernias should be operated with a tension-free technique. The use of mesh for the correction of large diameter hernias leads to a decrease in the recurrence rate. The surgical technique with mesh used in open surgery, placed to overlap the wall defect, yields a higher recurrence rate than the laparoscopic technique, where an intra-abdominal mesh technique is used [17]. The main purpose of this research work is to study and analyze the peculiarities of laparoscopic hernioplasty application, to improve the laparoscopic method used for surgical treatment of ventral, umbilical hernia, and to evaluate the advantages of this method for improving patients' quality of life, low risk of complications and fast rehabilitation.

## MATERIALS AND METHODS

The study is original, and an original method of surgical intervention was developed on its basis (report on the completion of the formal examination of the application for the invention on 16/06/2020<sup>1</sup> 13476 / 3A / 20). In the process of this research, we used a method of comparison, based on the surgical intervention by the method of TAPP and SUBLAY, performed in 405 patients. Among the total number of patients, 286 were female and 119 were male. The mean BMI among all patients was 29 t, the concomitant factor was excessive body weight. The laparoscopic technique in the treatment of ventral hernia was introduced in 2012 by IPOM and TAPP [13, 18]. In parallel, SUBLAY hernioplasty was performed, which was the method of choice in the treatment of ventral hernias until 2013. The work was performed based on the surgical department of the State Institution “SBL №1 of the Ministry of Health of Ukraine”.

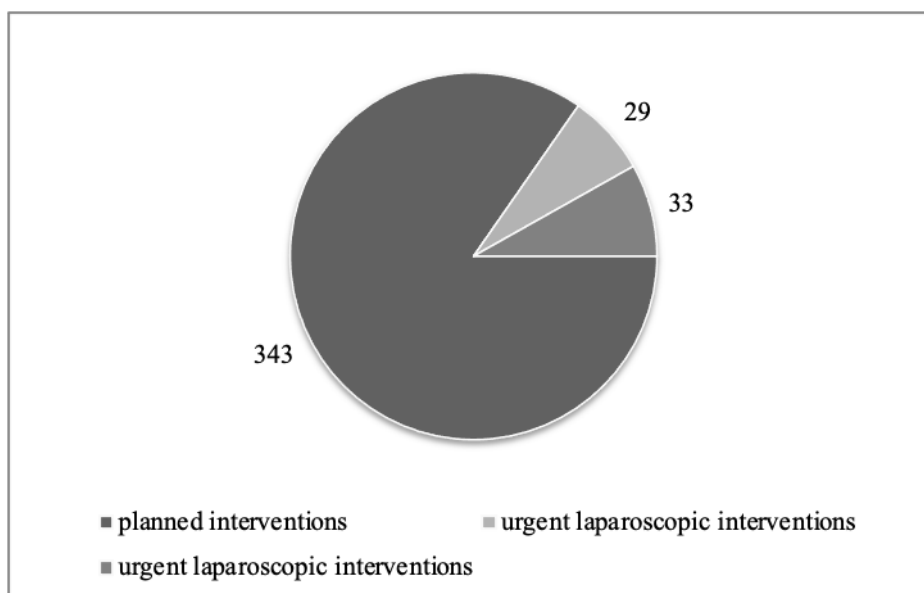
## RESULTS AND DISCUSSION

Surgical interventions were performed by two main methods - open preaponeurotic (Sublay) and laparoscopic transabdominal with the preperitoneal placement of the mesh prosthesis (TAPP). All patients on admission were given a general overview, anamnestic data collection, determination of IMT, a series of laboratory tests: complete blood count, urinalysis, biochemical blood count, coagulogram; determination of blood group and Rh factor; serological reactions to HIV, syphilis, hepatitis B and C. Among the instrumental investigations, there were ultrasound of the abdominal cavity organs and hernia sac, ECG. Patients over 40 years of age were examined by a cardiologist, echocardiography, and examination by an anesthesiologist. A part of the patients, by consent, was given a questionnaire according to the SF-36 form to assess their physical and psychoemotional state before surgical intervention and in the distant postoperative period. From 2013 to 2020, 405 patients were operated on with these methods in the department, of which: TAPP - 254 surgical interventions, SUBLAY - 151 surgical interventions (**Figure 1**).



**Figure 1.** The ratio of the number of TAPP and Sublay surgical interventions in the period from 2013 to 2020

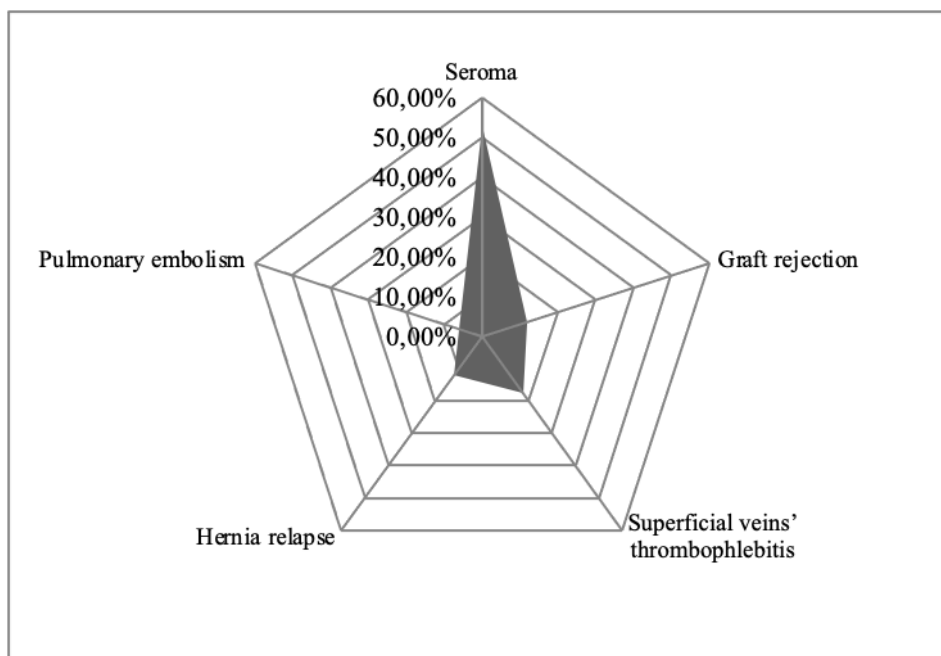
Among the total number of patients operated on, 62 patients were operated on for hernial impingement, for urgent indications: TAPP - 29 surgical interventions, SUBLAY - 33 surgical interventions (**Figure 2**).



**Figure 2.** The ratio of elective and urgent surgical interventions by TAPP and Sublay in 2013-2019

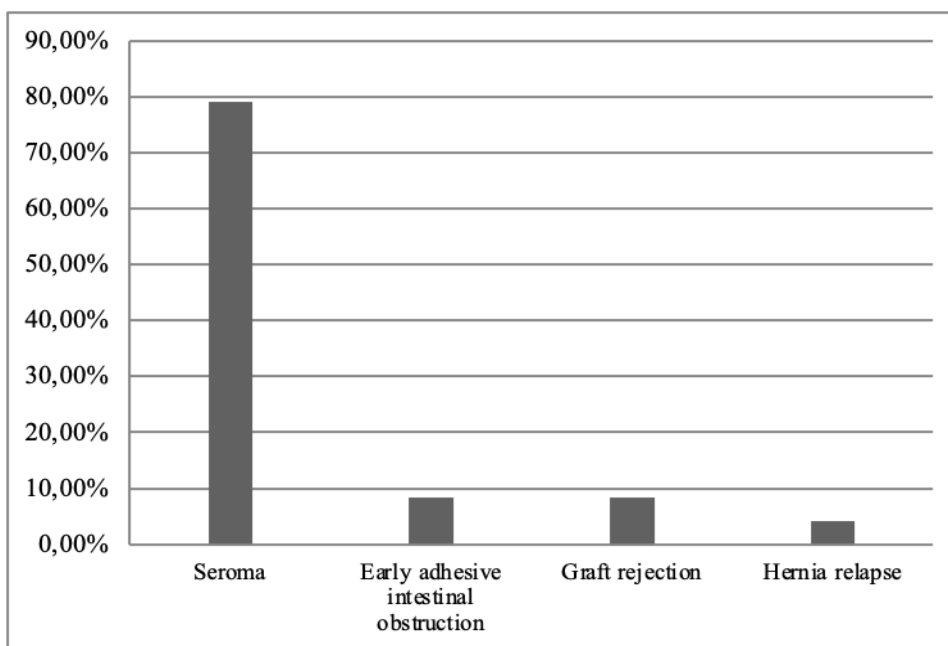
Hernioplasty was also performed using inlay, onlay, IPOM, and native tissue plastics because the clinical situation required it, but the number of these surgical interventions was insignificant and statistically unreported. In a quarter of surgical interventions, the author was an operator, in other cases - an assistant, and in 100% of the operated patients - an attending physician. Mesh prostheses used in hernioplasty: Duzeymesh (Turkey), Ultrapro J & J (USA), PromeshT Surgical IOS (France), and others manufactured in EU countries or the USA. Mesh prosthesis fixation and peritonealization were performed using Covidien Absorb tack, BARD SORBAFIX, Ethicon SECURESTRAP. Open preaponeurotic plastics were performed under end tracheal anesthesia and spinal anesthesia. After treatment of the surgical field with an antiseptic solution, a skin incision above the herniotomy sac was performed, with excision of the postoperative scar for postoperative ventral hernia, then the herniotomy sac was isolated up to the neck from the surrounding tissues. For small hernias with a small diameter of the herniotomy gate W1 per SWR classification, namely, in cases where the edges of the herniotomy gate could be brought together without difficulty, usually up to 2 cm in diameter, the prosthesis was placed preperitoneally (SPP - sublay preperitoneal). Fixation of the prosthesis was performed with anchor sutures through all aponeurosis layers to the subcutaneous fatty tissue. After that, the aponeurosis defect was sutured, the wound was sutured in layers blindly. In case of large size and volume hernias, retromuscular placement of the prosthesis (SRM - sublay retromuscular) was performed. In this case, after cutting off the hernia sac, the sheaths of the rectus muscles were dissected, the posterior leaves were isolated and sutured to each other with continuous sutures, and then the mesh prosthesis was placed on them, which was fixed to the subcutaneous fatty tissue through the muscles and anterior leaflet with anchor sutures. Next, the anterior leaves were sutured, and the postoperative wound was sutured tightly. Laparoscopic Transabdominal Preperitoneal Plastic (TAPP) was performed under endotracheal anesthesia. The patient's position on the operating table was standard, followed by transfer to Trendelenburg position for hernia M2-3 to M5, or to Fowler position for hernia M1-2 beyond the SWR classification. After treatment of the operating field with an antiseptic solution for M2-3 to M5, L3 hernias, the first trocar was inserted in the epigastric region along the median line, CO<sub>2</sub> peritoneum up to 12 mm was performed, after which one or two trocars were inserted in the lateral regions under visual control, according to the principle of triangulation of instruments in the abdominal cavity. After the revision of the abdominal cavity, organs were performed if it is necessary to move the contents of the hernia sac into the abdominal cavity. The next stage was the dissection of the parietal peritoneum in a semicircle along the neck of the hernia sac, and at some distance radially from it in the longitudinal plane. Separation of the peritoneum and displacement of the hernia sac into the abdominal cavity was performed. The central line of the anterior abdominal cavity and the M1-5, L3 area, respectively, have an anatomical feature - a pronounced layer of preperitoneal fatty tissue, allowing to perform peritoneal separation with the formation of a pocket for a mesh implant during the surgical intervention quite easily. In case of peritoneal deficiency, a hernia sac was also used for the peritonization of the prosthesis. If the hernial bulge is localized below the umbilicus and there are technical difficulties in peritonizing the prosthesis, the dissected iliac peritoneum is used along with the bladder,

which can be mobilized easily enough. The parietal peritoneum is dissected from the periosteum of the iliac bones in the direction of the pubic joint, the incision ends 3 cm higher. The technique is identical to the separation of the peritoneum in inguinal hernia surgery, but the volume of the dissected peritoneum is much larger, on one or both sides. This technique allows to peritonize a sufficiently large area of the prosthesis, moving the pinch of the peritoneum, and also allows performing prosthesis of all the weak points of the inguinal and iliac areas on both sides with a single large mesh prosthesis. Next, a mesh prosthesis was inserted into the abdominal cavity, which was at least 2 cm wider than the hernia gate on each side and fixed to the anterior abdominal wall. After that, when the pressure in the abdominal cavity decreased, peritonization of the prosthesis with detached leaves of the parietal peritoneum was performed. The last stage was desufflation and suturing of trocar wounds. For M1-2 localization of hernias, the video laparoscopic rack was placed at the head end of the operating table, the surgeon and operator were at the level of the patient's pelvis. The first trocar was inserted into the paraumbilical region. CO<sub>2</sub> peritoneum up to 12 mm was performed, the working trocars were placed and the further course of surgical intervention was performed according to the above-mentioned principle. After peritonealization of the prosthesis, the abdominal cavity was desaturated, the trocar wounds were sutured. The average hospital stay for open preaponeurotic hernioplasty was 7 days, and for laparoscopic hernioplasty - 4 days. In some cases, on the 5<sup>th</sup>-7<sup>th</sup> day after surgical intervention and in the distant postoperative period (6 months to 4 years), patients underwent ultrasound examination of the abdominal cavity organs with the assessment of the surgical intervention zone. The location of the prosthesis, type of vascularization using ultrasound Doppler, fibrous changes in the area of the prosthesis, the presence of adhesions in the surgical area, elastography of the postoperative scar area was considered. The total number of complications among 405 operated patients was 10.12%. Among the operations performed by open preaponeurotic plastics, the complication rate was 11.25% (17 cases). The most frequent complication was seroma development 52.9% (9 cases), transplant rejection was observed in 2 patients (11.8%). Thrombophlebitis of the lower limb superficial veins developed in 3 cases among all patients operated on by the "open" SUBLAY method, accounting for 17.6%. Hernia recurrence was observed in 2 patients (11.8%). Thromboembolism of small branches of the pulmonary artery developed in 1 patient and accounted for 5.9% of the total number of complications among the patients operated on using the SUBLAY method (**Figure 3**).



**Figure 3.** Frequency of complications among patients operated on using the SUBLAY method

The incidence of complications was lower among the patients operated on using laparoscopic preaponeurotic peritoneal plastics (TAPP) and amounted to 9.24% (24 cases). The most frequent complication was the development of seroma of the hernia sac area 79.2% (19 cases), the rate of early adhesive intestinal obstruction and necrosis of the navel skin was 8.3% each, hernia recurrence developed in 1 patient (4.2%) (**Figure 4**).



**Figure 4.** Frequency of complications among patients operated on by the TAPP method

The ultrasound picture in the early postoperative period was similar in both groups of operated patients - seroma was determined in the area of the fixed prosthesis. In the group of patients operated with the TAPP method, the width of the “peritoneum-mesh prosthesis-aponeurosis” complex was less than in the patients operated with the open preaponeurotic method. According to ultrasound data performed in the remote postoperative period, when comparing the area of surgical intervention in patients operated by the TAPP method to patients operated by the SUBLAY method, more complete and functional development of connective tissue in the area of mesh prosthesis location was determined. The thickness of the fibrous layer associated with the graft was thinner and more uniform, vascularization was smaller and more uniform. Also, the occurrence of adhesions in the surgical zone was less, the frequency of mesh implant displacement was significantly lower when using the laparoscopic method of surgical intervention. The follow-up period of patients operated on by the methods of open preaponeurotic and laparoscopic hernioplasty was 4 years. Based on the performed study, an original method of surgical intervention was developed, which consists of laparoscopic dissection of a large peritoneal flap from both sides of the iliac bone periosteum in the medial direction with dissection of the bladder for peritonealization of a polypropylene mesh prosthesis. This technique makes it possible to solve tactical and technical issues of treatment of ventral hernias of lower and medial localization at a higher quality level, actually up to the level of the paraumbilical area (M3).

The results of this study indicate a relatively low rate of complications in patients with umbilical, ventral, postoperative hernias operated on by two methods: open preaponeurotic SUBLAY method and laparoscopic preaponeurotic peritoneal TAPP. Accumulation of tissue fluid in the subcutaneous fatty tissue of the sutured wound (seromas) was observed in larger amounts when using the laparoscopic method of surgery. However, the development of such thrombotic complications as thromboembolism of small branches of the pulmonary artery and thrombophlebitis of surface veins of the lower limbs, which can cause a life-threatening condition for the patient, was observed in most cases when using open hernioplasty. A significant advantage of the laparoscopic preaponeurotic method was the shortened hospital stay, which significantly reduced the patient's recovery period and the level of financial losses. The obtained data closely correlate with similar studies conducted in Germany, proving significant advantages of the laparoscopic method of ventral hernia treatment to reduce the number of complications, recurrence, reduced hospital stay time, and rapid return from the usual activities of the patient. Immediate results of surgical treatment indicate certain advantages of using the TAPP method, namely: the rate of complications is less; easier course of the postoperative period; easier nature of complications. The analysis of the results of surgical treatment in the long-term postoperative period indicates more significant advantages of laparoscopic hernioplasty, as indicated by the lower incidence of complications and high quality of life in terms of physical and emotional health according to the SF-36 patient questionnaire. The analysis of the treatment results of patients with hernias of medium and lower localization proves that the TAPP method is advantageous over the SUBLAY method due to: lower frequency of early and late complications; the nature and

severity of complications after laparoscopic hernioplasty are more predictable; complications are easily correctable shortened hospital stay and rehabilitation period. Laparoscopic surgery was first introduced in the 1980s, is actively developing, and at the present stage is often the method of choice for certain surgical diseases. The advantage of laparoscopic methods of treatment is not only a low infection rate during surgery, fewer cases of intestinal obstruction, a faster recovery period, and better cosmetic, aesthetic effect, but also a lower mortality rate due to the use of less invasive accesses compared to laparotomy. Some studies show that the use of laparoscopic surgery reduces the rate of laparotomies performed from 14% to 6% [17]. New laparoscopic techniques are actively developing in herniology in particular, allowing their use even in complicated cases with comorbid diseases [19]. This research, like any other, has some limitations in that the results of this study are not based on randomized data. However, the advantage of this kind of research is the assessment of the real clinical situation, in the conditions of modern Ukrainian medicine. The priority of this scientific work is also the factor that allowed the study to be conducted among patients without artificial selection and transparency of all obtained data. Therefore, the use of such studies in the future can help doctors and scientists to focus on all the advantages and disadvantages of the methods used, to study and compare current and modern methods of treatment that can be applied in routine practice.

## **CONCLUSION**

Of course, the choice of surgical intervention method in the presence of hernias cannot be generalized, it is based in each particular case individually and depends on many factors. Such factors include not only the material and technical equipment of the medical institution, the experience of the surgeon, but also the presence of excess body weight and obesity, concomitant diseases of the respiratory and cardiovascular systems, the patient's age, the time of seeking medical care. The purpose of this study was to investigate the complications that may arise from both open preaponeurotic hernioplasty and laparoscopic technique to improve the results of treatment, avoid future recurrence and improve the quality of the patient's life. That is why the practical use of the modern laparoscopic method in the treatment of hernias of medium and lower localization is in most cases an alternative method, can be used even in severe, neglected cases, in the presence of chronic pathology, regardless of the patient's age. An important aspect that gives more advantages to the use of the laparoscopic hernioplasty method in patients is the socio-economic factor. After all, when the patient's hospital stay is reduced, the level of material costs decreases significantly, and the patient returns to normal activities and works more quickly. Laparoscopic technique for the treatment of hernias of medium and lower localization has a large number of supporters, both in Ukraine and in the world, who believe that the main advantage of this technique is the absence of contact with the free abdominal cavity and no reason for the formation of adhesions of the abdominal cavity organs, and therefore significantly reduced the risk of intra- and postoperative complications. Thus, the development and implementation of laparoscopic techniques show significant advantages in comparison with open laparotomy methods. Modern Ukrainian surgery and, in particular, herniology is steadily advancing, in correlation with modern European and world scientific data, the use of which in clinical practice, proves an undeniable advantage over traditional "classical" techniques.

**ACKNOWLEDGMENTS :** The author expresses his gratitude to the administration and staff of the surgical department of the State Institution "Specialized Multiprofile Hospital 1 of the Ministry of Health of Ukraine", Dnipro, Ukraine.

**CONFLICT OF INTEREST :** None

**FINANCIAL SUPPORT :** None

**ETHICS STATEMENT :** None

## **REFERENCES**

1. Gonzalez K, Chandler N. Ruptured omphalocele: Diagnosis and management. *Semin Pediatr Surg.* 2019;28(2):101-5.

2. Piatnochka VI, Dziubanovskyi IY, Prodan AM. Analysis of local and general complications in the treatment of primary hernias and postoperative ventral hernias for the period 2001-2017. *Bull Sci Res.* 2018;4:66-73 (in Ukrainian).
3. Fang CW, Chiu AW, Huang SK. Comparison of Single-Port Laparoscopic Totally Extraperitoneal Hernioplasty Versus Conventional Laparoscopic Totally Extraperitoneal Hernioplasty: A Single-Center Study. *Am Surg.* 2021;87(4):608-15. doi:10.1177/0003134820949999.
4. Ren-Zhang L, Chee-Lan L, Hui-Yin Y. The awareness and perception on Antimicrobial Stewardship among healthcare professionals in a tertiary teaching hospital Malaysia. *Arch Pharm Pract.* 2020;11(2):50-9.
5. Hanawi SA, Saat NZ, Zulkafly M, Hazlenah H, Taibukahn NH, Yoganathan D, et al. Impact of a Healthy Lifestyle on the Psychological Well-being of University Students. *Int J Pharm Res Allied Sci.* 2020;9(2):1-7.
6. Kroese LF, Kleinrensink GJ, Lange JF, Gillion JF, Ain JF, Beck M, et al. External validation of the European hernia society classification for postoperative complications after incisional hernia repair: a cohort study of 2,191 patients. *J Am Coll Surg.* 2018;226(3):223-9.
7. Shamsiev A, Davlatov S, Saydullaev Z. Optimization of treatment of patients with postoperative ventral hernia. *Sci Technol Educ.* 2017;40:94-9.
8. Piatnochka VI. Unresolved issues of surgical treatment of patients with postoperative ventral hernia given comorbidity. *Bull Sci Res.* 2017;1:11-5.
9. Froylich D, Segal M, Weinstein A, Hatib K, Shiloni E, Hazzan D. Laparoscopic versus open ventral hernia repair in obese patients: a long-term follow-up. *Surg Endosc.* 2015;30(2):670-5.
10. Khan S, Mian A. Medical education: COVID-19 and surgery. *Br J Surg.* 2020;107(8):e269. doi:10.1002/bjs.11740.
11. Rezk M, Saleh G, El-Gohary H, Allam A. Comparative Study between Heavy-weight Mesh and Light-weight Mesh in Ventral Hernia Repair. *Benha J Appl Sci.* 2020;5(6):1-6.
12. Bellido Luque JA, Bellido Luque A, Gomez Menchero J, Suarez Grau JM, García Moreno J, Tejada Gomez A, et al. Correction to: Safety and effectiveness of self-adhesive mesh in laparoscopic ventral hernia repair using transabdominal preperitoneal route. *Surg Endosc.* 2017;31(12):5463. doi:10.1007/s00464-017-5917-y. Erratum for: *Surg Endosc.* 2017;31(3):1213-8.
13. Chan EG, Sarkaria IS, Luketich JD, Levy R. Laparoscopic Approach to Paraesophageal Hernia Repair. *Thorac Surg Clin.* 2019;29(4):395-403. doi:10.1016/j.thorsurg.2019.07.002.
14. Omarov N, Tashtemirova O, Imangazinov S, Tashtemirov K, Kazangapov R. Surgical Treatment of Ventral Hernia in the Obese Patients. *Syst Rev Pharm.* 2020;11(12):1014-9.
15. Chen QL, Chen K, Huang DY, Pan Y, Yan JF, Wang XF, et al. Trans-umbilical single-incision laparoscopic trans-abdominal pre-peritoneal hernioplasty of inguinal hernia by self-made glove port. *Medicine (Baltimore).* 2020;99(34):e21787. doi:10.1097/MD.00000000000021787.
16. Olavarria OA, Bernardi K, Shah SK, Wilson TD, Wei S, Pedroza C, et al. Robotic versus laparoscopic ventral hernia repair: multicentre, blinded randomized controlled trial. *BMJ.* 2020;370:m2457. doi:10.1136/bmj.m2457.
17. Alfa-Wali M, Osaghae S. Practice, training and safety of laparoscopic surgery in low and middle-income countries. *World J Gastrointest Surg.* 2017;9(1):13.
18. Luo S, Wu S, Lai H, Mo X, Chen J. Single-Incision Laparoscopic Inguinal Hernioplasty Versus Conventional Laparoscopic Inguinal Hernioplasty. *Surg Innov.* 2017;24(2):171-82. doi:10.1177/1553350617690308.
19. Schwarz J, Reinhold W, Bittner R. Endoscopic mini/less open sublay technique (EMILOS)—a new technique for ventral hernia repair. *Langenbecks Arch Surg.* 2016;402(1):173-80.