



Original Article

ISSN : 2277-3657
CODEN(USA) : IJPRPM

Estimation of Left Ventricular Filling Pressure by Assessment of Left Atrial Contractile Function Using Cardiovascular Magnetic Resonance Volumetry

Alhobgani Tariq^{1*}, Awwad Fuad¹, Albackr Hanan¹, AlHabeeb Waleed¹, Fayez ElShaer^{1,2}

¹King Fahad Cardiac Center, Department of Cardiac Sciences, College of Medicine, King Saud University, Riyadh, Saudi Arabia.

²National heart institute, Cairo, Egypt.

*Email: tariqmfh@yahoo.com

ABSTRACT

The purpose of this study was to assess the relationship between left atrial contractile function, as quantified by cardiac magnetic resonance (CMR) volumetry, and left ventricular end-diastolic pressure (LVEDP). We assessed 26 patients with impaired left ventricular systolic function using steady-state free precession CMR volumetry. The percentage of left atrial contraction contribution (ACC) to left ventricular (LV) filling was determined. It was calculated by dividing LV volume resulting from LA contraction by LV stroke volume (LVSV). We used, as a reference group, data from a previously published study of 120 normal subjects where ACC was calculated using the same method. All patients had Doppler echocardiography, where E/Ea ratio was calculated, and left heart catheterization was done to measure LVEDP. There was no difference between ACC in patients with LVEDP less than 20 mmHg and ACC in normal subjects ($P=0.2$). There was a significant difference between ACC in patients with LVEDP more than 20mmHg and normal subjects ($P<0.0001$). When ACC was adjusted for age, i.e. dividing ACC percentage by age, a value less than 0.41 detected elevated LVEDP ($>20\text{mmHg}$) with a sensitivity and specificity of 93% and 88%, respectively. In patients with impaired LV systolic function, the quantification of ACC to LV filling using CMR volumetry is a simple and reliable method to assess LVEDP.

Key words: Left atrial function, Left atrial contribution, Left ventricular filling, Cardiovascular magnetic resonance

INTRODUCTION

In patients with cardiomyopathy, elevated LV end-diastolic pressure (LVEDP) correlates with the degree of heart failure symptoms, independently of the severity of systolic dysfunction [1-3]. Therefore, assessment of LVEDP might be of an important clinical use. Using non-invasive imaging, several parameters such as Doppler and tissue Doppler echocardiography have been described to evaluate LVEDP. None of these parameters is free from limitations, grey zones, and false results [4]. Cardiovascular magnetic resonance (CMR) has become the gold standard for LV volumes measurement, as it can acquire high-quality images in any selected plane or along any selected axis [5]. This study aims to use CMR volumetry to measure the atrial contraction contribution (ACC) to LV filling in patients with LV dysfunction and evaluate its relation to LVEDP.

MATERIALS AND METHODS

Study population

Prospectively, we enrolled patients with LV systolic dysfunction referred for cardiac catheterization. All patients had a CMR scan. For a reference for the normal ACC, 50 normal subjects were evaluated. Informed consent was taken from all patients.

Cardiovascular MR technique and image analysis

CMR was performed using a 3.0 Tesla Siemens with a dedicated 32-channel surface coil [6-9]. Volumes were calculated from 8 to 10 short-axis views using a standard steady-state free precession (SSFP) sequence. Retrospective ECG gating was used to allow full coverage of the cardiac cycle. The volume resulting from atrial contraction was measured by subtracting the LV volume before the atrial contraction (named as $V1$) from the LV-end diastolic volume (named as $V2$). The phase of $V1$ was defined by being the last image before the late mitral valve opening, best seen in the 3-chamber view, as well as by visualizing the atrial contraction. This method to calculate the ACC was described in a previous study that included 120 normal subjects [10]. All contours were traced manually excluding papillary muscles from volumes (**Figure 1**). In the short-axis approach, volumes were calculated using the modified Simpson's rule. LV was covered by 8 to 10 slices. The basal slice was included in the calculations if a clear LV myocardial border was identified in 50% or more of the circumference, and excluded if it was less than 50% visible. Forty CMR studies were reviewed by another expert reader to assess inter-observer variability.

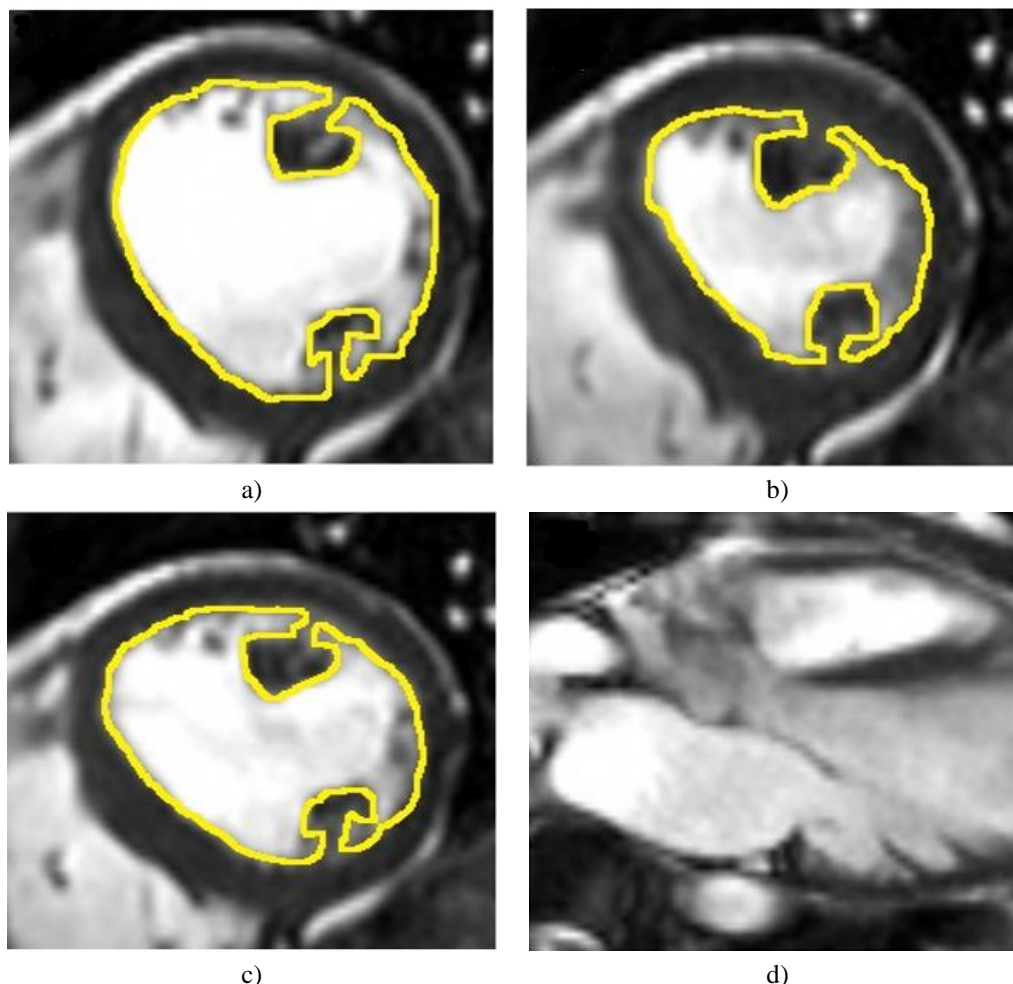


Figure 1. Endocardial Contours Drawn Manually in the Short Axis View by CMR
a) LV end-diastolic volume ($V2$). b) LV end-systolic volume. c) LV volume before atrial contraction and before late mitral valve opening ($V1$). d) Three-chamber long axis view was used to determine the phase of $V1$ (the LV volume just before LA contraction).

Echocardiography

Echocardiography studies included assessments of LV systolic function, valvular function, and mitral inflow Doppler study and tissue Doppler (TD) of both the septal and the lateral mitral valve annulus in the apical four-

chamber view. The early diastolic (Ea) velocity by TD at the septal and lateral annular sites was measured and the E/Ea ratio was computed from the average of the septal and lateral Ea because this approach has been shown to yield optimum accuracy [11]. The echocardiography reader was blinded to CMR and clinical data. LV filling pressure was defined as normal when E/Ea was less than 8 and elevated when E/Ea was above 15. Patients with E/Ea ratio between 8 to 15 were considered to have a borderline value since this range was found to be a poor independent predictor of LV filling pressure [12, 13].

LVEDP measurement

All patients had left heart catheterization to measure LVEDP except 2 patients because of significant aortic stenosis. LVEDP measurement was performed within 6 hours of the CMR and echocardiography. We defined LVEDP as maximal pressure drop after pressure increase due to atrial contraction and before the rise of systolic pressure. The aim was to study the relationship between LVEDP and ACC as quantified by CMR.

RESULTS AND DISCUSSION

Patients' characteristics are shown in **Table 1**.

Four patients were excluded from the study (two had no LVEDP measurement because of severe aortic stenosis and the others received intravenous nitroglycerin which may result in a reduction of LVEDP before undergoing CMR scan). The agreement between the two readers was excellent, as the *P* value of the mean difference between the two readers was >0.1 for all measured volumes. **Figure 2** shows the atrial contraction contribution adjusted for the age (ACC/age) against LVEDP for 26 patients with impaired LVEF. There was an inverse correlation between them. Statistical analysis was performed for all 76 subjects to find out the best value of ACC/age to discriminate between normal and elevated LVEDP. Sensitivity and specificity were calculated for all Acc/Age values. **Figure 3** shows the receiver operating characteristics (ROC) curve where the area under the curve (AUC) was calculated to be 0.958. The ACC/Age cutoff value of 0.41 was found to have the best combination of sensitivity and specificity of 0.93 and 0.88, respectively, to discriminate between normal and elevated LVEDP. E/Ea sensitivity and specificity to detect LVEDP >20 were 77% and 85%, respectively. Six patients (four with LVEDP >20 and two with LVEDP <12) had a borderline E/Ea ratio (E/Ea between 8 and 15), but all had a determined predictive (ACC/Age) value that correlated well with LVEDP.

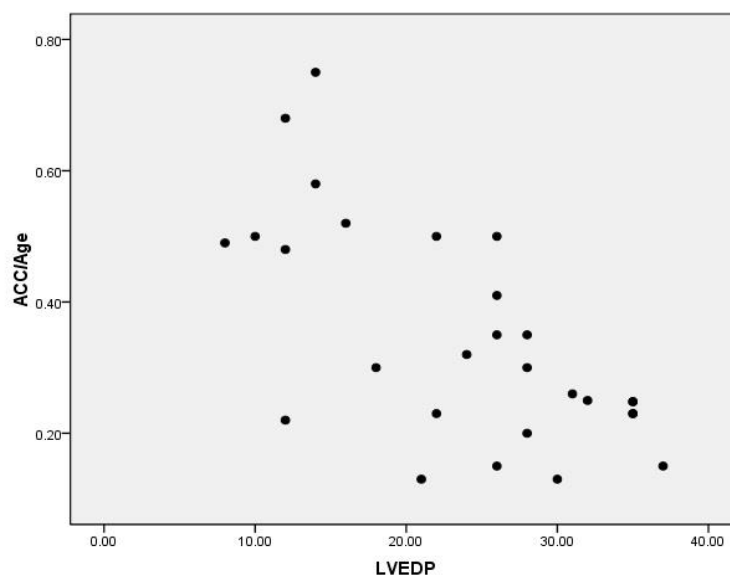


Figure 2. ACC/Age vs LVEDP

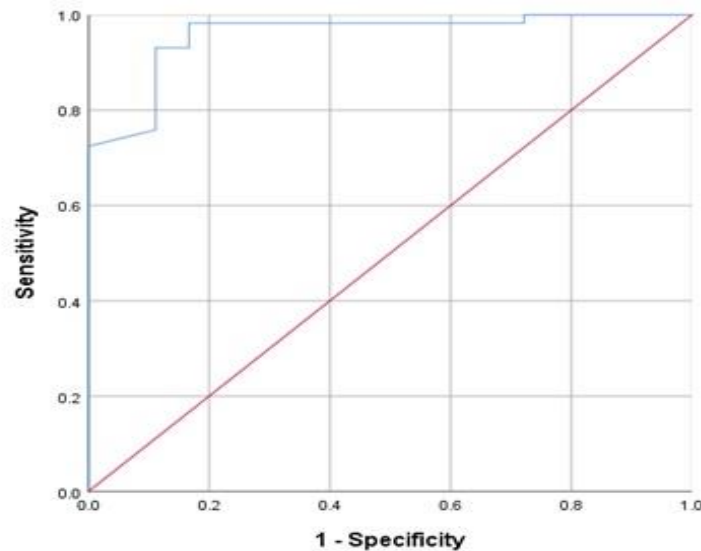


Figure 3. Receiver Operating Characteristics (ROC) Curve for the Estimation of Elevated LVEDP by ACC/Age (AUC: 0.958).

Table 1. Patients' Characteristics.

Variable	Patients with Impaired LV Function	Normal Subjects
Age (years)	53±28	47±18
Male%	54%	50%
Heart rate*	79±9	72±10
E Velocity (cm/s)	85±27	72±15
E/E' Medial Annulus	18±12	6±3
E/E' Lateral Annulus	15±9	5±2
E/A	1.4±1.6	1.3±0.6
CMR Data:		
LVEF	30%±10	61±4
V1 (ml)	200±55	142±31
V2 (ml)	228±55	176±34
LVSV (ml)	78±26	87±16

Comments on the method of MRI study

The study used a direct LV volumetry method to quantify ACC to LV filling. It could be possible to acquire a mitral inflow study by CMR trying to evaluate LV filling pressure. However, this technique is well known to suffer from significant artifacts. It also prolongs total scan time, in contrast to our described method which does not require extra CMR sequences apart from the standard images taken for LV systolic function assessment. We preferred LV to LA volumetry, as the latter may overestimate ACC because of the expected reversal of flow during atrial contraction into pulmonary veins especially in case of elevated LVEDP. Efforts were taken to obtain optimal measurements, including the use of SSFP sequence and retrospective gating to allow coverage of atrial end-systole.

Comments on the results

A good correlation was found between elevated LVEDP (>20mmHg) and decreased ACC. This reduction in ACC is either due to high LV pressure at the time of atrial systole or due to chronic impairment of atrial contractile function. Although clinically it might not be important, a repeated CMR study after the reduction of LVEDP is required to determine which etiology could be true. The cut-off value of 0.41 for ACC/Age was chosen, as it gave the best combination of sensitivity and specificity to detect elevated LVEDP. Impairment of left atrium contractile function in patients with elevated LV filling pressure is well reported by echocardiography studies. Our study presents a novel CMR method that gives a sensitive cut off value for the detection of elevated LVEDP.

The reported sensitivity and specificity of tissue Doppler echocardiography to detect elevated LVEDP is variable according to the used cut-off value of E/Ea and LVEDP. The result found in our study is close to what is reported by several studies [13-16]. In contrast to tissue Doppler echocardiography which studies mitral annulus motion, assessment using our CMR method takes into consideration motion of all LV segments and this is a probable explanation of having higher sensitivity.

Study limitations

The study did not include patients with EF>50%, and thus the validity of this method is unknown in such patients. Caution should be taken when interpreting a result that is close to the borderline value (0.41) since variability in drawing contours might affect the result.

CONCLUSION

Quantification of ACC to LV filling using CMR volumetry is a reliable method to estimate LVEDP in patients with impaired LV systolic function. This method might be combined with other surrogate makers such as Doppler echocardiography to increase the accuracy of LV filling pressure estimation by non-invasive tools.

ACKNOWLEDGMENTS : We thank Ms. Rowayda Alhogbani for providing language help.

CONFLICT OF INTEREST : None

FINANCIAL SUPPORT : None

ETHICS STATEMENT : None

REFERENCES

1. Fink LI, Wilson JR, Ferraro N. Exercise ventilation and pulmonary artery wedge pressure in chronic stable congestive heart failure. *Am J Cardiol.* 1986;57(4):249-53.
2. Franciosa JA, Baker BJ, Seth L. Pulmonary versus systemic hemodynamics in determining exercise capacity of patients with chronic left ventricular failure. *Am Heart J.* 1985;110(4):807-13.
3. Szlachcic J, Massie BM, Kramer BL, Topic N, Tubau J. Correlates and prognostic implication of exercise capacity in chronic congestive heart failure. *Am J Cardiol.* 1985;55(8):1037-42.
4. Nagueh SF, Appleton CP, Gillebert TC, Marino PN, Oh JK, Smiseth OA, et al. Recommendations for the evaluation of left ventricular diastolic function by echocardiography. *Eur J Echocardiogr.* 2009;10(2):165-93.
5. Rademakers FE. Magnetic resonance imaging in cardiology. *Lancet.* 2003;361(9355):359-60.
6. Alzahrani S, Alosaimi ME, Oways FF, Hamdan AO, Suqati AT, Alhazmi FS, et al. Knowledge of Cardiovascular Diseases and Their Risk Factors among the Public in Saudi Arabia. *Arch Pharm Pract.* 2019;10(3):47-51.
7. Taheri F, Masoudi S, Soltani Z. Diagnosis of Cardiovascular Disease Using Fuzzy Methods in Nuclear Medicine Imaging. *Arch Pharm Pract.* 2019;10(4):118-26.
8. Aniss NN, Rahman YHA, Zaazaa AM. Cardioprotective Effect of Moringa Oleifera Against Doxorubicin Cardiotoxicity in Leukemia Rat Model. *Int J Pharm Phytopharmacol Res.* 2020;10(2):148-61.
9. Vallipriya R, Begum MS. Cardio-Protective Effects of Ipomea Biloba Against the Myocardial Infarction in Rats. *Int J Pharm Phytopharmacol Res.* 2020;10(2):74-81
10. Alhogbani T, Strohm O, Friedrich MG. Evaluation of left atrial contraction contribution to left ventricular filling using cardiovascular magnetic resonance. *J Magn Reson Imaging.* 2013;37(4):860-4.
11. Hill JC, Palma RA. Doppler tissue imaging for the assessment of left ventricular diastolic function: a systematic approach for the sonographer. *J Am Soc Echocardiogr.* 2005;18(1):80-90.
12. Ommen SR, Nishimura RA, Appleton CP, Miller FA, Oh JK, Redfield MM, et al. Clinical utility of Doppler echocardiography and tissue Doppler imaging in the estimation of left ventricular filling pressures: a comparative simultaneous Doppler-catheterization study. *Circulation.* 2000;102(15):1788-94.
13. Kasner M, Westermann D, Steendijk P, Gaub R, Wilkeshoff U, Weitmann K, et al. Utility of Doppler echocardiography and tissue Doppler imaging in the estimation of diastolic function in heart failure with

- normal ejection fraction: a comparative Doppler-conductance catheterization study. *Circulation*. 2007;116(6):37-47.
14. Mullens W, Borowski AG, Curtin RJ, Thomas JD, Tang WH. Tissue Doppler imaging in the estimation of intracardiac filling pressure in decompensated patients with advanced systolic heart failure. *Circulation*. 2009;119(1):62-70.
 15. Poorrafsanjani MH, Darabad BR. Evaluate the sensitivity and specificity echocardiography in trans-Doppler and tissue Doppler method in the estimation of left ventricular end-diastolic pressure. *Glob J Health Sci*. 2014;6(7):92-7.
 16. Dagdelen S, Eren N, Karabulut H, Akdemir I, Ergelen M, Saglam M, et al. Estimation of left ventricular end-diastolic pressure by color M-mode Doppler echocardiography and tissue Doppler imaging. *J Am Soc Echocardiogr*. 2001;14(10):951-8.