



Original Article

ISSN : 2277-3657
CODEN(USA) : IJPRPM

Comparison between Magnetic Resonance Imaging and Ultrasound in Diagnosing Uterine Fibroids in Hail Area, Saudi Arabia

Qurain Turki AlShammari^{1*}, Mezna AlHouty², Bushra Abdel Malik¹, Mohammed Salih¹, Saleh Abdulkareem AlRumyan³, Meshari T AlShammari¹, Rahaf Alshareef⁴, Elgeili Yousif¹

¹Department of Diagnostic Radiology, College of Applied Medical Sciences, University of Hail, Hail, Saudi Arabia.

²Department of the Radiological, Maternity and Children Hospital, Hail Health Cluster, Ministry of Health, Saudi Arabia.

³Radiation Protection Program, Ministry of Health, Riyadh, Saudi Arabia.

⁴Department of Science in Physics, College of Sciences, University of Imam Mohammad Ibn Saud Islamic, Riyadh, Saudi Arabia.

*Email: g.algrain@uoh.edu.sa

ABSTRACT

Uterine fibroids (also known as leiomyomas or myomas) are the most common benign uterine tumors. Aim of the study: We aimed to evaluate the role and potential of Magnetic resonance imaging (MRI) to add information to the ultrasound report by comparing the total number, size, and location of fibroids present. This is a comparative cross-sectional study including 50 patients, aged from 20 to 50 years; they were diagnosed as uterine fibroids patients by ultrasound. The data were obtained from the Picture Archiving and Communication system (PACs) from October 2021 to June 2022 G. The examination was performed on a GE, Philips, Mindray, and Hitashi ultrasound scanner and an MRI machine from Siemens 1.5T and 3T. The examination is done in the lower abdomen. The technique protocol meets the standard of the American Institute of Ultrasound in Medicine (AIUM). There are differences between Magnetic resonance imaging and ultrasound in the purpose of diagnosing uterine fibroids, in which a higher percentage is (100%) referred to diagnosing uterine fibroids by Magnetic resonance imaging. The analysis shows that 92% of the uterine fibroids were diagnosed by ultrasound and that 8% of the uterine fibroids were not diagnosed. In addition to ultrasound, we concluded that MRI could be preferentially utilized for and add some information for assessing Uterine fibroids especially small fibroids with a diameter of 1 cm or less.

Key words: *Magnetic resonance imaging, Ultrasound, Fibroid, Uterus*

INTRODUCTION

Uterine fibroids (also known as leiomyomas or myomas) are the most common benign uterine tumors, with a 20–40% incidence in women during their reproductive ages. Even though their pathogenesis is unknown, there is substantial evidence that estrogens and progestogens promote tumor growth [1]. The majority of UFs are discovered during routine pelvic examinations or by chance during imaging; symptoms are influenced by the size, number, and location of the tumor. The two most common symptoms that lead women to seek treatment are abnormal uterine bleeding and pelvic pressure [2]. An accurate assessment of the size, number, and position of myomas is required for the optimal selection of patients for medical therapy, noninvasive procedures, or surgery. Sonography and MRI are imaging techniques that can be used to confirm the diagnosis of myomas [1]. On

ultrasound, fibroids are usually easy to spot, though focal adenomyosis can look like a fibroid and a pedunculated uterine fibroid can be mistaken for an adnexal mass. When there is doubt about the origin of a pelvic mass after an ultrasound, an MRI should be performed [1]. While more expensive, magnetic resonance imaging has been hailed as the most sensitive modality for evaluating uterine myomas, particularly for the detection of small fibroids. As a result, MRI is more sensitive than ultrasound in detecting uterine fibroids [1, 3].

MATERIALS AND METHODS

This is a comparative cross-sectional study including 50 patients. Inclusion or selection criteria were women with low back pain, bleeding, or bloating, aged from 20 to 50 years, diagnosed as uterine fibroids patients by ultrasound and transferred to the Magnetic resonance imaging unit, to see what MRI information might add. The data was obtained from the picture archiving and communication systems (PACs). Analyzed by statistical software packages (SPSS). The patient attended the Radiological Department, Hail – Maternity and Children Hospital (MCH), and Hail – King Salman Hospital, Saudi Arabia, from October 2021 to June 2022 G, the examinations were performed on a GE, Philips, Mindray, and Hitashi ultrasound scanner and an MRI machine from Semens 1.5T and 3T. The examinations were done in the lower abdomen and explained to the patient. The technique protocol meets the standard of the American Institute of Ultrasound in Medicine (AIUM) (Figures 1 and 2).

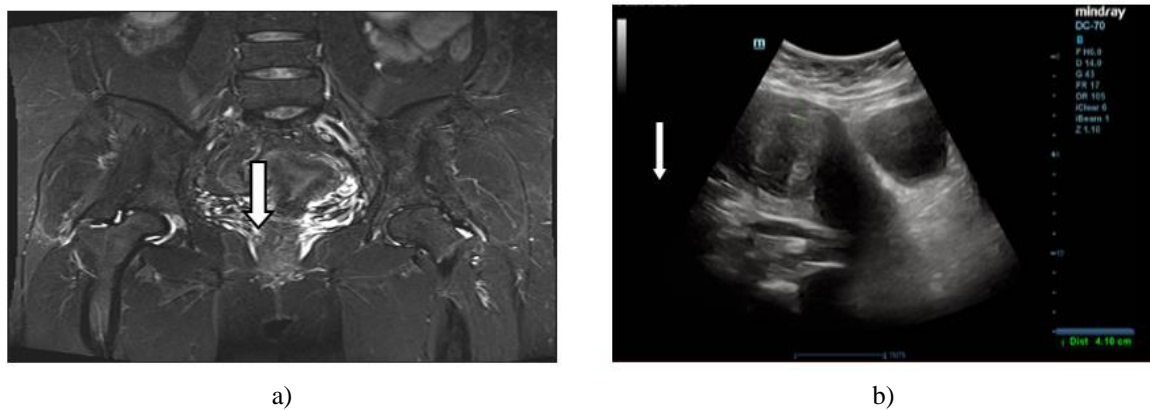


Figure 1. 43-year-old woman with uterine fibroid

a) MRI, T2 stir coronal show uterine fibroids (arrow) T2 heterogeneous signal, subserous location, size 5.07 cm, b)US, Sagittal transabdominal sonogram shows one fibroid (arrow) hypoechoic in the uterus, heterogeneous, size 7.5 × 5.5 cm and subserous location.

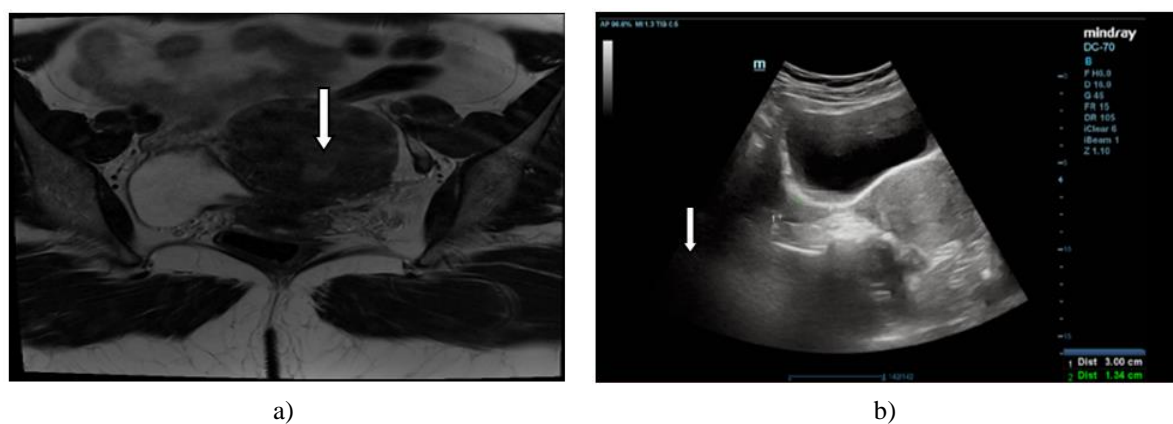


Figure 2. 49-year-old woman with uterine fibroid

a) MRI, T2 transverse show uterine fibroids (arrow) T2 heterogeneous signal Low T2 signal, subserous location, measured about 1.8 × 1.9 cm, b) US, transverse transabdominal sonogram shows one fibroid (arrow) hypoechoic in the uterus, heterogeneous, subserous location.

Statistical analysis

Data were collected from patients arriving at the MRI unit at the King Salman Specialist Hospital who were referred from the Maternity and Children Hospital in Hail, and diagnosed with uterine fibroids by ultrasound. All study tools used are in the PACs system attached to the MRI unit. Data were collected in the tabulated database sheet and analyzed using SPSS version 20 IBM.

RESULTS AND DISCUSSION

According to the **Table 1**, there is a difference between MRI and US in the number of Uterine Fibroids. The distribution of sonographic findings of uterine fibroids was demonstrated in **Table 1**: 46% of single uterine fibroids, 2 uterine fibroids (22%), 3 uterine fibroids (20%), 4 uterine fibroids (4%), and (8%) of uterine fibroids not seen by ultrasound. Furthermore, MRI shows about 42% of single uterine fibroids, 2 uterine fibroids (24%), 3 and 4 uterine fibroids (14%), and 5 uterine fibroids (6%) (**Figure 3**). According to the **Table 1**, there is a difference between MRI and US findings in the size of Uterine Fibroids, length of the uterine fibroids by ultrasound is less than 4 cm, from 4-8 cm, and more than 8 cm, around 41%, while by MRI it is 47.2%, 36.1%, and 16.7% of less than 4 cm, from 4-8 cm, and more than 8 cm respectively (**Figure 4**).

According to the **Table 1**, There is a difference between MRI and US in the location of uterine fibroids. The percentages frequency of uterine fibroids location by ultrasound is 43.9%, 19.3%, 3.5%, 21.1%, 7%, and 5.3% for Intramural, Submucosal, Submucosal Pedunculated, Subserosal Pedunculated, and Subsesosal, respectively. As shown in **Table 2**. MRI Location of Uterine Fibroids frequency are: Cervical, intramural, Submucosal Pedunculated, Subserosal Pedunculated, and Subsesosal since the percentage is 1.4%, 44.3%, 18.6%, 2.9%, 18.6%, 2.9%, 18.6%, 7.1%, and 7.1%, respectively (**Figure 5**).

Table 1. Frequencies and percentages distribution of MRI and US finding of uterine fibroids

Variables	Categories	US		MRI	
		F	%	F	%
Seen	Yes	46	92.0	50	100.0
	No	4	8.0	-	-
Number	0	4	8.0	-	-
	1	23	46.0	21	42.0
	2	11	22.0	12	24.0
	3	10	20.0	7	14.0
	4	2	4.0	7	14.0
	5	-	-	3	6.0
Size (CM): Length	Less than 4 cm	34	41.0	51	47.2
	From 4-8 cm	35	42.2	39	36.1
	More than 8 cm	14	16.9	18	16.7
Size (CM): Width	Less than 4 cm	35	42.2	47	43.5
	From 4-8 cm	34	41.0	43	39.8
	More than 8 cm	14	16.9	18	16.7
Location	Cervical	-	-	1	1.4
	Intramural	25	43.9	31	44.3
	Submucosal	11	19.3	13	18.6
	Submucosal Pedunculated	2	3.5	2	2.9
	Subserosal	12	21.1	13	18.6
	Subserosal Pedunculated	4	7.0	5	7.1
	Subsesosal	3	5.3	5	7.1

Table 2. Descriptive statistics for age and No. of pregnancy variables

Variable	Categories	Value
Age	N	50
	Mean	40.20
	Max	50
	Min	25
	Median	43
	Mode	50
Number of pregnancy	N	50
	Mean	3.30
	Max	7
	Min	0
	Median	3
	Mode	0

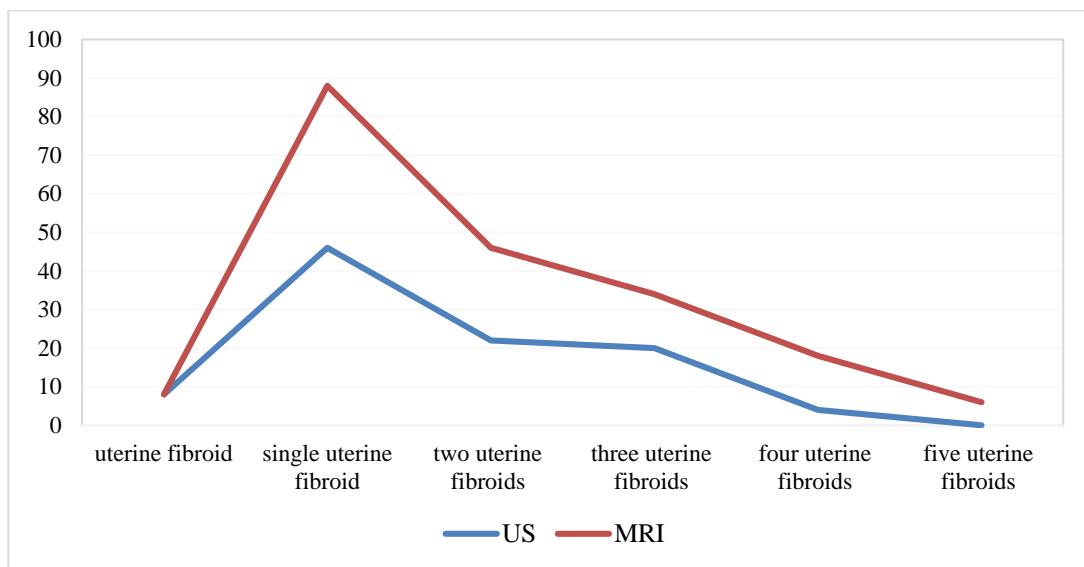


Figure 3. Differences between MRI and US in the number of uterine fibroids

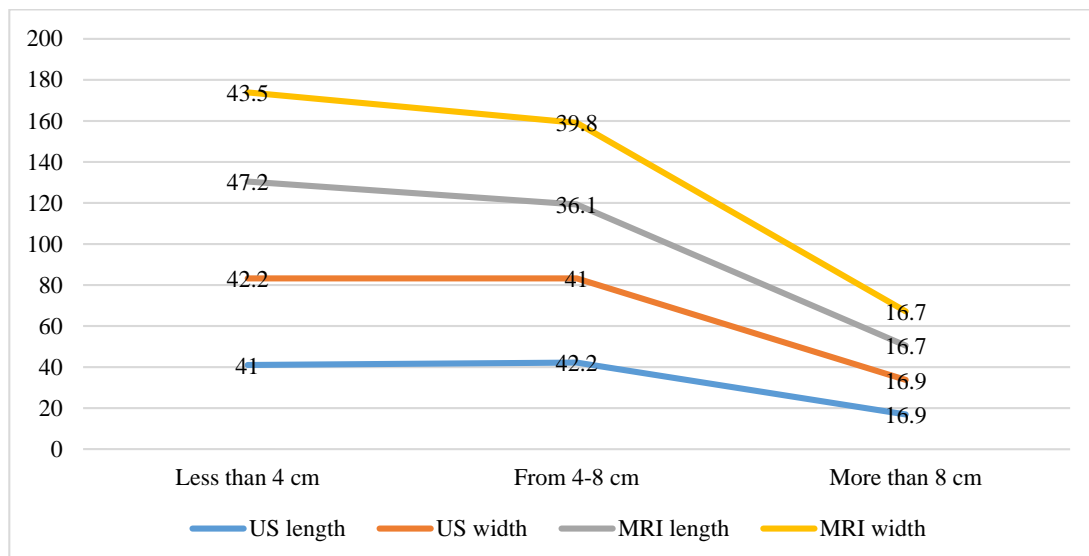


Figure 4. Differences between MRI and US in size uterine fibroids

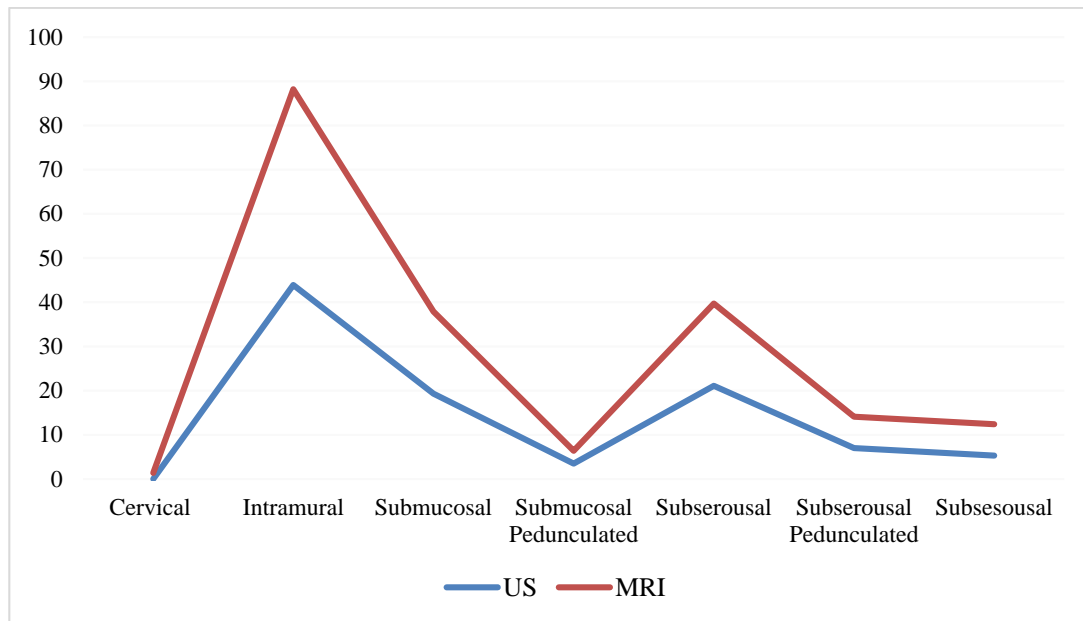


Figure 5. Differences between MRI and US in a location of uterine fibroids

The current study found that uterine fibroids detected by ultrasound, added more information when rescanning by MRI, especially small fibroids with a diameter of 1 cm or less, and several studies have shown this. This finding is consistent with previous studies done by Hossain *et al.*, which compared Study of Magnetic Resonance Imaging and Transabdominal Ultrasonography for the Diagnosis and Evaluation of Uterine Fibroids [4].

The present study found that, according to **Table 1**, there is a difference between MRI and US findings in the size of Uterine Fibroids, this Result showed agreement with, Audrey L Spielmann *et al.*, which compared of MRI and sonography in the preliminary evaluation for fibroid embolization [5].

The comparison of the accuracy of the ultrasound scanning and magnetic resonance imaging for detecting uterine fibroids was specifically addressed here in terms of the number of tumors, their size, and location, taking into account the importance and features of each device and the capabilities of the technician and radiologist as they play a major role in the examination results. This finding was also the same as the study done by Am J Obstet Gynecol *et al.* [6].

In this study US and MRI have the same high level to detect uterine fibroids, this agrees with the study done by: Dueholm, *et al.* (The presence of myomas was detected with the same high level of precision by both methods (magnetic resonance imaging: sensitivity, 0.99; specificity, 0.86; transvaginal ultrasonography: sensitivity, 0.99; specificity, 0.91) [7]. (1 In patients with 1 to 4 myomas, diameter measurements had equal and high accuracies [7].

In **Table 2**, the incidence of uterine fibroids, increase by age and number of pregnancy, this support previous research by Onchee Yu, *et al.* [8, 9].

Limitations

The reliability of this data is affected by the time between ultrasound and MRI scans. Because uterine fibroids increase in size rapidly over three to six months, so due to the length of time, it is normal for the size of the fibroids to change and their number may change as well. Most patients with uterine fibroids were over 50 years of age and were outside the scope of this study.

CONCLUSION

The experience and skill of a doctor and Radiology technician have a major role in the high resolution of the examination results. The advantage of ultrasound over MRI is, Ultrasound is fast (the speed of examination and result), available (availability of the device), and low cost, but it requires special skill. Magnetic Resonance Imaging is characterized by its high resolution and disadvantages in the high cost and length of examination time.

In this study, we conclude that magnetic resonance imaging in some cases can add some information to the ultrasound.

ACKNOWLEDGMENTS : We would like to thank the clinical staff and Radiologists at the radiology department of University of Hail, College of Applied Medical Sciences, Radiological Department, Hail – Maternity and Children Hospital (MCH), and Hail – King Salman Hospital, Saudi Arabia for their generous help.

CONFLICT OF INTEREST : None

FINANCIAL SUPPORT : None

ETHICS STATEMENT : None

REFERENCES

1. Khan AT, Shehmar M, Gupta JK. Uterine fibroids: current perspectives. *Int J Womens Health.* 2014;6:95-114.
2. Singh SS, Belland L. Contemporary management of uterine fibroids: focus on emerging medical treatments. *Curr Med Res Opin.* 2015;31(1):1-2.
3. Tetreault L, Nakashima H, Kato S, Kryshchak M, Nagoshi N, Nouri A. A Systematic Review of Classification Systems for Cervical Ossification of the Posterior Longitudinal Ligament. *Global Spine J.* 2019; 9(1):85-103. doi:10.1177/2192568217720421
4. Hossain MZ, Rahman MM, Ullah MM, Mukthadira M, Akter FA, Jahan AB, et al. A Comparative Study of Magnetic Resonance Imaging and Transabdominal Ultrasonography for the Diagnosis and Evaluation of Uterine Fibroids. *Mymensingh Med J.* 2017;26(4):821-7.
5. Spielmann AL, Keogh C, Forster BB, Martin ML, Machan LS. Comparison of MRI and sonography in the preliminary evaluation for fibroid embolization. *AJR Am J Roentgenol.* 2006;187(6):1499-504. doi:10.2214/AJR.05.1476
6. Levens ED, Wesley R, Premkumar A, Blocker W, Nieman LK. Magnetic resonance imaging and transvaginal ultrasound for determining fibroid burden: implications for research and clinical care. *Am J Obstet Gynecol.* 2009;200(5):537-e1. doi:10.1016/j.ajog.2008.12.037
7. Dueholm M, Lundorf E, Hansen ES, Ledertoug S, Olesen F. Accuracy of magnetic resonance imaging and transvaginal ultrasonography in the diagnosis, mapping, and measurement of uterine myomas. *Am J Obstet Gynecol.* 2002;186(3):409-15.
8. Yu O, Scholes D, Schulze-Rath R, Grafton J, Hansen K, Reed SD. A US population-based study of uterine fibroid diagnosis incidence, trends, and prevalence: 2005 through 2014. *Am J Obstet Gynecol.* 2018;219(6):591-e1.
9. Zepiridis LI, Grimbizis GF, Tarlatzis BC. Infertility and uterine fibroids. *Best Pract Res Clin Obstet Gynaecol.* 2016;34:66-73.