



Original Article

ISSN : 2277-3657  
CODEN(USA) : IJPRPM

## ***Hepatoprotective Activity of Calycopteris floribunda on Clopidogrel and Atorvastatin Induced Hepatic Damage in Rodents***

**Jada Naga Lakshmi<sup>1\*</sup>, Polimera Chaitanya Sai<sup>2</sup>, Pulipati Sowjanya<sup>3</sup>, Puttagunta Srinivasa Babu<sup>3</sup>, Sandeep Kanneganti<sup>4</sup>, Sreenu Thalla<sup>1</sup>**

<sup>1</sup>Department of Pharmacology, Vignan Pharmacy College, Jawaharlal Nehru Technological University, Vadlamudi 522213, Andhra Pradesh, India.

<sup>2</sup>Department of Pharmacology, Chalapathi Institute of Pharmaceutical Sciences, Acharya Nagarjuna University, Guntur-522034, Andhra Pradesh, India.

<sup>3</sup>Department of Pharmaceutics, Vignan Pharmacy College, Jawaharlal Nehru Technological University, Vadlamudi 522213, Andhra Pradesh, India.

<sup>4</sup>Department of Hospital Pharmacy, Starcare Hospital, Muscat Oman.

\*Email: [drjnlpharmacology@gmail.com](mailto:drjnlpharmacology@gmail.com)

---

### ABSTRACT

Preclinical testing hepatoprotective potential of hydroalcoholic leaf extract of *Calycopteris floribunda* against liver damage caused by atorvastatin and clopidogrel. Atorvastatin and clopidogrel were delivered intraperitoneally for 14 days at 80mg/kg and 20mg/kg respectively, while leaf extract was given orally for the same period at 200mg/kg and 400mg/kg. To evaluate the impact of the leaf extract on the atorvastatin and clopidogrel-induced liver damage, many biochemical markers, Serum glutamate pyruvate transaminase (SGPT), serum glutamate oxaloacetate transaminase (SGOT), total protein, and serum alkaline phosphatase were measured. Blood samples from mice given hydroalcoholic *Calycopteris floribunda* leaf extract showed a noteworthy decrease in serum indicators, suggesting that the leaf extract had an impact on the hepatocytes' ability to operate normally again. On the other hand, the mice receiving atorvastatin and clopidogrel treatment showed increased levels, which suggested serious liver injury. Silymarin (100 mg/kg) was given as a benchmark. The current investigation found that *Calycopteris floribunda* hydroalcoholic extract significantly protected the liver against atorvastatin and clopidogrel-induced hepatic damage.

**Key words:** *Calycopteris floribunda*, SGOT, SGPT, TP

---

### INTRODUCTION

The liver is the principal metabolic organ that participates in the metabolism of necessary substances. Apart from its function in metabolism, it is crucial for both endogenous and foreign molecule detoxification and excretion, protecting the body from harmful poisons. Damage to the liver occurred as a result of exposure to xenobiotics and their metabolites over an extended period. Additionally, the liver is involved in almost every biochemical pathway for growth, disease prevention, nutrient absorption, and energy metabolism [1]. Infections, excessive alcohol intake, toxic substances, and autoimmune diseases are the main causes of liver ailments. The majority of hepatotoxic substances primarily cause lipid peroxidation and other oxidative damage to liver cells. The liver is the only organ that can naturally regenerate. Despite enormous advancements in contemporary medicine, there are no effective medications that can improve the function of the liver, protect the liver against harm from ions, or increase the regeneration of hepatic cells [2].

Statins inhibit the mevalonate pathway, which is a rate-limiting enzyme in the synthesis, of cholesterol HMG-CoA reductase (hydroxymethyl glutaryl-CoA synthase), and as a result, lower cholesterol levels. The most popular and regularly used statin is atorvastatin. In both humans and rats, the metabolic conversion of atorvastatin to ortho and para-hydroxy atorvastatin is carried out by CYP3A/CYP3A4, which is a toxic metabolite may responsible for the hepatocyte damage [3].

It is claimed that tannins, flavanol, octacesanol, sitosterol, 3-methylcalycopterin, 4-methylcalycopterin, ellagic acid, gossypol, quercetin, proanthocyanidin, calycopterin, calycopterin methyl ester, and oxymethyl calycopterin are present in the leaves of the *Calycopteris floribunda* plant [4].

*Calycopteris floribunda* is one of the ethnomed plants that is frequently used to make specific herbal medications. Its various parts are used to treat a variety of conditions, including astringent, laxative, hepatotoxic, neurotoxic, cardiotoxic, antimicrobial, antioxidant, antiviral, anti-inflammatory, ulcerative, pruritus, colic, leprosy, malarial fever, dysentery, vomiting, skin diseases, and more. *C. floribunda* is a plant with several therapeutic applications that may be used to treat a range of illnesses without having any typical negative effects [5].

A species known as *Calycopteris floribunda* belonging to the Family Combretaceae, also known as *Combretum extensum* Roxb, is native to Malabar and other regions of South India.

## MATERIALS AND METHODS

### *Animals*

We purchased animals from Mahavir Enterprises in Hyderabad, weighing 200–250 g Wistar rats of any sex. One week before the experiment began and throughout, the animals were kept under conventional settings, which included a temperature of  $22 \pm 1^\circ\text{C}$ , a 12-hour light and dark cycle, and relative humidity of  $60 \pm 5\%$ ., following the rules and regulations of the Institutional Ethics Committee and the government's animal regulatory body (Reg.No:1048/PO/Re/S/07/CPCSEA) with approval number 07/IAEC/CLPT/2022-23. They received water on demand and a standard lab lunch from M/s. Rayans Biotechnologies Pvt. Ltd., Hyderabad.

### *Plant material*

The *Calycopteris floribunda* leaves used in this study were obtained from the plant's natural environment around the town of Chittoor. Dr. P. Satyanarayana Raju, M.Sc., MPhil., Ph.D., of the Department of Botany and Microbiology at Acharya Nagarjuna University, verified the authenticity of the leaves.

### *Plant extraction*

30% water and 70% methanol were used to extract fresh, dried powdered *Calycopteris floribunda* leaf material in a Soxhlet device that was maintained at  $68^\circ\text{C}$  for 72 hours. The mixture was filtered using Whatman No. 1 membrane filter paper and vacuum-dried at  $45^\circ\text{C}$  to calculate the extract's yield, expressed as a percentage (180 rpm using a rotary evaporator) [6].

### *Preliminary phytochemical screening*

Using the accepted method outlined by Kokate [7] and Harborne [8] for preliminary phytochemical screening, the process was completed (**Table 1**).

**Table 1.** Initial phytochemical screening of *Calycopteris floribunda* hydroalcoholic extract

Type of constituents	Hydroalcoholic leaf extract
Triterpenes	Present
Steroids	Present
Carbohydrates	Absent
Tannins	Present
Flavonoids	Present
Alkaloids	Present
Glycosides	Absent
Saponins	Present

### Induction of hepatotoxicity

Albino Wistar rats were administered 80 mg/kg and 20 mg/kg of clopidogrel and atorvastatin intraperitoneally (i.p.) for 14 days in order to induce hepatotoxicity.

Mitochondrial damage is one of the mechanisms that cause statin-induced hepatic damage. The potency of a statin and its impact on the cytochrome P450 system both enhanced the likelihood of liver damage brought on by a statin. The production of reactive oxygen species and cytochrome P450-dependent metabolism contribute to cell death. Statin use increases lipid peroxidation and the formation of ROS, which decreases mitochondrial membrane potential and causes cytotoxicity [9].

CYP450-metabolized medicines can increase the risk of hepatitis. Atorvastatin and clopidogrel are both metabolized by CYP4503A4. The fact that CYP4503A4 converts clopidogrel into its active metabolite while this enzyme metabolizes atorvastatin predominantly puts more strain on the enzyme, which may increase liver enzyme levels and result in drug-induced hepatitis. Clopidogrel has demonstrated a synergistic impact in this instance, which induces severe liver damage [10].

### Hepatoprotective activity

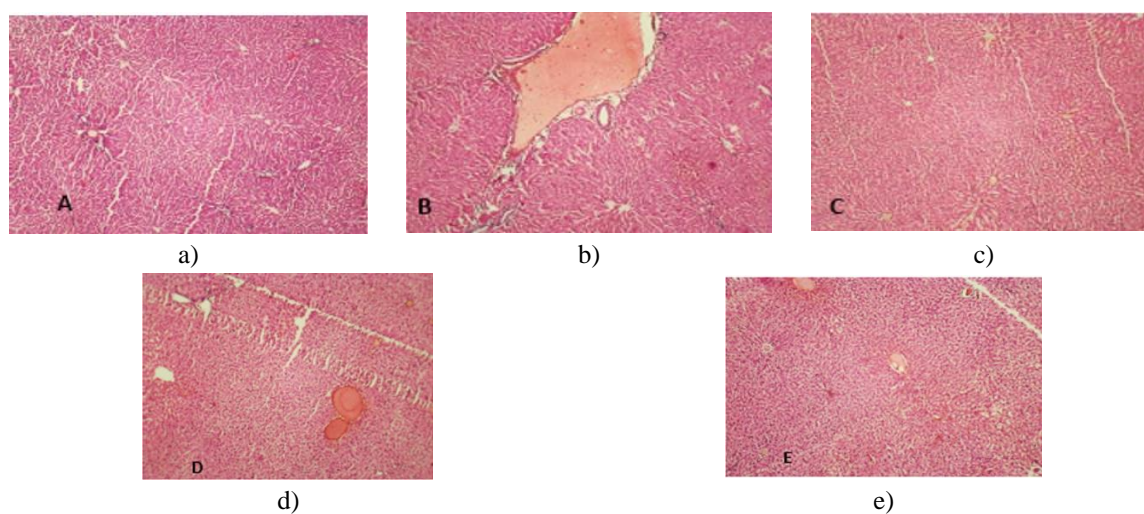
The study employed five animals in each group, a total of five groups. For 14 days, animals in group I served as the normal control group and received 5 ml/kg (b.w.) of normal saline daily. Animals from group II were treated similarly to those from group I because they were hepatotoxic. For 14 days, groups IV and V were given hydroalcoholic leaf extract suspended in sodium carboxymethylcellulose (0.5%) at doses of 200 and 400 mg/kg/day, respectively, whereas group III got the conventional medication silymarin (100 mg/kg; p.o. daily) for the same period. Except for the rats in group I, all rats were administered atorvastatin and clopidogrel in a dose of 80mg/kg and 20mg/kg (b.w.) respectively for 14 days. The rats were fasted for the whole duration of the trial, and then they were put to death under cervical dislocation. For biochemical and histological research, blood and liver samples were taken [11].

### Biochemical studies

Using retro-orbital plexus punctures, each blood sample was collected and placed separately in sterile, dry centrifuge tubes. The samples were then allowed to coagulate for 30 minutes at 37 °C. The biochemical tests for serum glutamic oxaloacetate transaminase (SGOT), serum glutamic pyruvate transaminase (SGPT), alkaline phosphatase (ALP), and total bilirubin (TB) were then carried out on the clear serum that had been separated in a microcentrifuge at 2500 rpm for 10 minutes.

### Histopathological examination

Each Rat's liver was removed, cleaned with sterile saline, and preserved in 10% formalin. Using tap water, formalin-fixed tissue was washed. It was then serially dehydrated in ethanol and cleaned in xylene. Finally, paraffin wax was used to implant xylene-cleared tissue. The paraffin-embedded block was cut into sections that were 4-5 microns thick, and they were then stained for histopathological analysis with hematoxylin and eosin. The preparation and examination of microscopic slides under a microscope (**Figure 1**) [12].



**Figure 1.** Histology of hepatocytes treated with standard and test. a) Vehicle Control, b) Negative Control, c) Standard, d) Test-I, e) Test-II.

## Statistical analysis

Each parameter was examined independently, and the data was analyzed using a one-way analysis of variance (ANOVA), revealing substantial intergroup differences. For individual comparisons, Dunnet's test was employed. A statistically significant value is one with a p-value of less than 0.05.

## RESULTS AND DISCUSSION

Preliminary phytochemical analysis of the hydroalcoholic leaf extract of *Calycopteris floribunda* revealed the presence of steroids, triterpenes, tannins, alkaloids, saponins, and flavonoids. Because the hydroalcoholic leaf extract of *Calycopteris floribunda* did not cause any rat deaths up to a level of 3000 mg/kg (b.w.), a dose of 200 and 400 mg/kg was selected for the assessment. The table summarises the effects of hydroalcoholic *Calycopteris floribunda* leaf extract on serum transaminase, total protein, bilirubin, and alkaline phosphatase levels in rats with liver damage caused by atorvastatin and clopidogrel (**Table 2**). The hepato-specific serum indicators SOD, AST, ALP, and total protein were significantly ( $P < 0.05$ ) elevated in the atorvastatin and clopidogrel administered group compared to the healthy control group after receiving atorvastatin (80mg/kg; b.w.) and clopidogrel (20mg/kg) for 2 weeks of intoxication (**Tables 3 and 4**). After receiving Silymarin at a dose of 100 mg/kg (Group III) and hydroalcoholic leaf extract of *Calycopteris floribunda* (Groups IV & V), the level of these enzymes was observed to be returning to normal.

**Table 2.** Effect of hydroalcoholic leaf extract of *Calycopteris floribunda* on serum biochemical parameters

S/N	Groups	ALP (mg/dl)	AST(IU/L)	ALT (IU/L)
1	Control (Normal saline-5ml/kg)	86.2 ± 1.24	21.4 ± 1.68	18.6 ± 0.66
2	Negative control (Atorvastatin-80mg/kg+ clopidogrel-20mg/kg)	254 ± 7.07	292 ± 6.78	79.6 ± 2.63
3	Standard (Silymarin-100mg/kg)	168 ± 6.35	161.2 ± 2.92	22.4 ± 1.06
4	Test -I ( <i>Calycopteris floribunda</i> -200mg/kg)	205.4 ± 3.32	219.6 ± 3.95	17.7 ± 0.93
5	Test-II ( <i>Calycopteris floribunda</i> -400mg/kg)	126.3 ± 6.86	146.3 ± 2.63	21.8 ± 0.96

All values are shown as mean ± SEM, n=6.

**Table 3.** Effect of hydroalcoholic extract of *Calycopteris floribunda* on serum biochemical parameters

S/N	Groups	TB (mg/dl)	TP (mg/dl)	SOD(U/g.tissue)
1	Control (Normal saline-5ml/kg)	0.45 ± 0.03	0.91 ± 0.01	6.7 ± 0.2
2	Negative control (Atorvastatin-80mg/kg+ clopidogrel-20mg/kg)	3.6 ± 0.101	4.81 ± 0.02	13.6 ± 0.06
3	Standard (Silymarin-100mg/kg)	0.6 ± 0.06	0.8 ± 0.05	8.32 ± 0.43
4	Test -I ( <i>Calycopteris floribunda</i> -200mg/kg)	0.38 ± 0.06	0.2 ± 0.02	7.5 ± 0.22
5	Test-II ( <i>Calycopteris floribunda</i> -400mg/kg)	0.34 ± 0.05	0.48 ± 0.04	7.2 ± 0.23

All values are shown as mean ± SEM, n=6.

**Table 4.** Impact of *Calycopteris floribunda* hydroalcoholic extract on serum biochemical parameters

S/N	Groups	AST(IU/L)	ALT (IU/L)	MDA (nM of MDA /mg protein)
1	Control (Normal saline-5ml/kg)	146.5 ± 1.436	51.75 ± 1.391	0.45 ± 0.22

2	Negative control (Atorvastatin-80mg/kg+ clopidogrel-20mg/kg)	186.4 ± 2.644	86.2 ± 2.725	1.14 ± 0.04
3	Standard (Silymarin-100mg/kg)	154.62 ± 2.844	60.76 ± 1.684	0.58 ± 0.04
4	Test -I ( <i>Calycopteris floribunda</i> -200mg/kg)	169.24 ± 1.455	66.7 ± 1.307	0.58 ± 0.02
5	Test-II ( <i>Calycopteris floribunda</i> -400mg/kg)	141.44 ± 1.654	62.5 ± 1.725	1.44 ± 0.03

All values are shown as mean ± SEM, n=6.

Because of the liver's unique anatomic location and function, it is vulnerable to numerous types of chronic injury [13]. Using its cellular antioxidant system, the liver can destroy free radicals created during the metabolism of numerous drugs and xenobiotics. OS growth is sped up and liver dysfunction results from the increased production of free radicals and decreased antioxidant defense in liver cells [14, 15]. Multiple chronic liver disorders (CLDs) have an important role for OS in their etiology. Growing data supports the idea that OS plays a role in the etiology of CLD that is brought on by both chemicals and medications [16]. Cholestasis, cirrhosis, necrosis, and fibrosis are symptoms of long-term liver injury [17].

The blood levels of bilirubin, ALP, and aminotransferases, taken as blood biomarkers of liver function, according to David *et al.* (2014), [18] with a rise in these indicators indicating hepatic impairment. However, when there is hepatic injury, the levels of total protein and albumin are decreased.

The minimal changes in ALT, AST, and ALP blood levels as well as total bilirubin levels in liver damage demonstrate that therapy of normal rats with *Calycopteris floribunda* had no detrimental effects. Since atorvastatin and clopidogrel significantly raised the activity of the liver function marker enzymes ALT, AST, ALP, SGOT, SGPT, MDA, and bilirubin in the serum of rats, the results of the current investigation provided evidence in favor of the notion that the drug has hepatotoxic effects. These results are in line with earlier studies.

Rats treated with atorvastatin and clopidogrel had substantially lower elevated levels of ALT, AST, ALP, and bilirubin after pretreatment with *C. floribunda*. The stabilizing effect of the *C. floribunda* phytochemical constituent(s) and other active ingredients on the hepatocytes' plasma membrane may be responsible for the decrease in these serum biomarker levels. This stabilizing effect is likely caused by the stimulation of hepatocellular protein synthesis and the ability to induce microsomal enzymes, either by preventing oxidative stress brought on by clopidogrel or by quickening the excretion of atorvastatin and clopidogrel.

The current study's demonstration of the plant's hepatoprotective activity came from the enzyme levels returning to normal range following the administration of *C. floribunda* extract. Maintaining the physiological activities of the hepatic organs injured by hepatotoxins is a powerful criterion for evaluating whether any hepatoprotective treatment is useful. Similar observations have also been seen from several other plant species, including Red Lentil [19] and *Aerva lanata* [20].

The effect was demonstrated to be comparable to widely used drugs (Silymarin). The bulk of the data shows that the liver treated with atorvastatin and clopidogrel has an unbalanced antioxidant system, which is corrected by the antioxidant properties of *C. floribunda* extract. Using histological examination, the hepatoprotective efficacy of the *C. floribunda* extract was further examined. *C. floribunda* extract can inhibit atorvastatin and clopidogrel hepatotoxicity, according to the findings of serum biochemical studies and the histological analysis of liver samples. They demonstrate a broad spectrum of biological and pharmacological effects because flavonoids frequently scavenge free radicals and play a significant role in lowering oxidative stress.

*C. floribunda* extract pretreatment protected liver tissue from tissue disorganization and necrosis as well as from prominent areas of sinusoidal, central vein, and hepatic parenchymal tissue mononuclear infiltration. This was achieved by stopping oxidative stress, harmful chemical reactions, and molecular alterations in the liver tissues that cause necrosis.

The plant's enhanced hepatocellular architecture demonstrated the hepatoprotective effects of *C. floribunda* in the liver of pretreated rats intoxicated with atorvastatin and clopidogrel.

## CONCLUSION

Liver illness is among the most important medical conditions. When allopathic medicine is unable to provide effective protective drugs for a range of liver issues, herbs are employed as treatments. Since the last few years,

there has been a considerable increase in our understanding of liver illnesses, which has had an impact on how we diagnose and treat hepatic issues. We attempted to investigate the hepatoprotective properties of a locally accessible plant in our study. By evaluating the prevention of atorvastatin and clopidogrel-induced hepatotoxicity in rats, our research intends to better understand the therapeutic effect of the hydroalcoholic extract of *Calycopteris floribunda*. The biochemical, functional, and histological data indicate that the plant *Calycopteris floribunda* exhibits strong hepatoprotective action.

**ACKNOWLEDGMENTS :** We acknowledge the principal and management of Vignan Pharmacy College, Chalapathi Institute of Pharmaceutical Sciences, for their support to carry out this work.

**CONFLICT OF INTEREST :** None

**FINANCIAL SUPPORT :** None

**ETHICS STATEMENT :** Study was approved by IAEC of Chalapathi Institute of Pharmaceutical Sciences with approval number 07/IAEC/CLPT/2022-23

## REFERENCES

1. Singh A, Verma P, Shukla MK. A comprehensive review on hepatoprotective activity of some medicinal plants. *Int J Pharm Sci Drug Res.* 2023;8(2):664-72.
2. Patel J, Kumar GS, Ahirwar K, Gupta MK, Singh SK, Chandel SS, et al. Comparative analysis in hepatoprotective activity of crude extracts of important medicinal plants. *Res J Pharm Technol.* 2023;16(2):659-62.
3. Zeng H, Liu Z. Atorvastatin induces hepatotoxicity in diabetic rats via oxidative stress, inflammation, and anti-apoptotic pathway. *Med Sci Monit: Int Med J Exp Clin Res.* 2019;25:6165.
4. Rajasekaran A, Periasamy M. Hepatoprotective effect of ethanolic leaf extract of calycopteris floribunda lam on cadmium-induced hepatotoxicity in rats. *Res J Pharm, Biol Chem Sci.* 2012;3(3):382-90.
5. Azhagumeena C, Bharathi PR. A review on phytochemistry and pharmacology of calycopteris floribunda roxb. lam. *Int J Chem Res.* 2020;4(4):1-8.
6. Nikhal S, Dambe P, Ghongade D, Goupale D. Hydroalcoholic extraction of mangifera indica (leaves) by soxhletion. *Int J Pharm Sci.* 2010;2(1):30-2.
7. Kokate C. Preliminary phytochemical analysis. *Practical Pharmacognosy 1st ed New Delhi: Vallabh Prakashan.* 1986;111.
8. Harborne J. Methods of extraction and isolation. *Phytochem Methods.* 1998;3:60-6.
9. Averbukh LD, Turshudzhyan A, Wu DC, Wu GY. Statin-induced liver injury patterns: A clinical review. *J Clin Transl Hepatol.* 2022;10(3):543-52.
10. Thotakura S, Singh A, Khera K, Chauhan S, Devasia T. Atorvastatin-induced hepatotoxicity, increased by clopidogrel stress on CYP450 Enzyme: Understanding the mechanism through a case. *J Appl Pharm Sci.* 2018;8(4):168-70.
11. Ayenew KD, Wasihun Y. Hepatoprotective effect of methanol extract of agave americana leaves on paracetamol induced hepatotoxicity in Wistar albino rats. *BMC Complement Med Ther.* 2023;23(1):1-8.
12. Ali SA, Sharief NH, Mohamed YS. Hepatoprotective activity of some medicinal plants in Sudan. *Evid Based Complementary Altern Med.* 2019;2019. doi:10.1155 /2019/2196315
13. Fruci B, Giuliano S, Mazza A, Malaguarnera R, Belfiore A. Nonalcoholic fatty liver: A possible new target for type 2 diabetes prevention and treatment. *Int J Mol Sci.* 2013;14(11):22933-66.
14. Echeverría F, Valenzuela R, Bustamante A, Álvarez D, Ortiz M, Soto-Alarcon SA, et al. Attenuation of high-fat diet-induced rat liver oxidative stress and steatosis by combined hydroxytyrosol-(HT)-eicosapentaenoic acid supplementation mainly relies on HT. *Oxid Med Cell Longev.* 2018;2018.
15. Tiao MM, Lin YJ, Yu HR, Sheen JM, Lin I, Lai YJ, et al. Resveratrol ameliorates maternal and post-weaning high-fat diet-induced nonalcoholic fatty liver disease via the renin-angiotensin system. *Lipids Health Dis.* 2018;17(1):1-11.
16. Homma T, Kurahashi T, Lee J, Nabeshima A, Yamada S, Fujii J. Double knockout of peroxiredoxin 4 (Prdx4) and superoxide dismutase 1 (Sod1) in mice results in severe liver failure. *Oxid Med Cell Longev.* 2018;2018.

17. Arab JP, Arrese M. Old remedies to heal the liver: Novel effects of digoxin in hepatic sterile inflammation. *Hepatology*. 2019;69(2):904-6.
18. Kleiner DE, Chalasani NP, Lee WM, Fontana RJ, Bonkovsky HL, Watkins PB, et al. Hepatic histological findings in suspected drug-induced liver injury: Systematic evaluation and clinical associations. *Hepatology*. 2014;59(2):661-70.
19. Rahmani A, Goudarzi M, Rashidi Nooshabadi M, Houshmand G, Khadem Haghighian H. Protective effect of red Lentil (*Lens Culinaris*) extract against carbon tetrachloride-induced hepatotoxicity in mice. *J Babol Univ Med Sci*. 2014;16(2):49-55.
20. Kanchana N, Sadiq AM. Hepatoprotective effect of plumbago zeylanica on paracetamol induced liver toxicity in rats. *Int J Pharm Pharm Sci*. 2011;3(1):151-4.