



Original Article

ISSN : 2277-3657  
CODEN(USA) : IJPRPM

## ***Ki-67 Immunohistochemical Evaluation of Changes in Gastric Stem Cell Population with Age***

**Tahani Ahmad Al-Matrafi<sup>1</sup>, Muhammad Atteya<sup>1\*</sup>**

<sup>1</sup>Department of Anatomy, College of Medicine, King Saud University, Riyadh, Saudi Arabia.

\*Email: [mhasan1@ksu.edu.sa](mailto:mhasan1@ksu.edu.sa)

---

### ABSTRACT

Digestive diseases resulting from atrophy and metaplasia become more common as people get older, resulting in anatomical and functional abnormalities in the gastrointestinal system. The integrity and health of all parts of the digestive system depend largely on the presence of an adequate stem cell population. The study aimed to analyze the gastric stem cell population of different ages, using Ki-67 immunohistochemistry. Twenty-one adult male albino rats were distributed into 3 age groups, each consisting of 7 rats: Juvenile, Adult, and Old. After one acclimatization week, all animals were euthanized. The stomach was excised and processed for histological staining with H&E and Ki-67 immunohistochemical staining. The Ki-67 slides were subjected to image analysis and the percentage of positive cells was counted. The staining was predominantly nuclear with varying intensities. Statistical analysis revealed that the Ki-67 nuclear staining mean intensity score was slightly higher in the Adult group than in the Juvenile and Old groups, with no significant differences. Statistical analysis also showed significantly fewer stem cells in both the Adult and Old age groups than in the Juvenile group. The Old group also showed fewer stem cells than the adult group, but the difference was not statistically significant. The gastric stem cell population decreases with age.

**Key words:** Immunohistochemistry, Ki-67, Cell proliferation, Gastric stem cells, Age

---

### INTRODUCTION

The stomach is a sophisticated organ with distinctive physiological and biochemical functions [1]. Mucosa, submucosa, muscularis, and serosa are the four layers of the stomach wall [2]. The mucosa is thrown into folds and shows gastric pits which are the openings of the gastric glands which produce enzymes and hydrochloric acid (HCl). The epithelium is made up of a variety of cell types comprising surface mucous cells, mucous neck cells, oxyntic cells, peptic cells, enterochromaffin cells, and regenerative stem cells.

During the first month of life, the most intensive reconstruction process took place [3]. The rat stomach is immature in development and function at birth, and it remains so until postnatal day 14 when it undergoes significant morphological and physiological changes at around postnatal day 21 when muscularis mucosae and lamina propria collagenization are well established. The stomach of rat or dog does not secrete hydrochloric acid after birth. Regardless, hydrochloric acid is secreted by the rabbit and pig stomachs at birth. Increased thickness of gastric glandular mucosa and peptic cells maturation are both parts of stomach postnatal development [4].

When compared to adults, there are fewer peptic cells in the newborn, and the peptic cells in neonates are unable to synthesize pepsin. The number of peptic cells rises as postnatal development advances, contributing to the increasing thickness of the mucosa [4]. Mucous neck cells oxyntic cells are present at birth. In neonates, the number of oxyntic cells is two to three folds that in adults, although the mucosa and muscle layers are thinner [4,

5].

Diet, age, genetic determinants, intestinal hormones, and other factors are all mentioned in the scientific literature as influencing postnatal gastrointestinal growth [6]. In mammals, the transition from amniotic fluid to milk occurs almost immediately after birth. At weaning, the diet shifts when milk is gradually replaced as the primary source of nourishment with solid food [7, 8].

The gut undergoes a variety of changes as people age. Malnutrition and cachexia can occur quickly when the intestinal epithelium loses its absorptive ability, which is especially dangerous for the aged and feeble [9, 10].

The decrease in motor activity of several GI functions, for example emptying of the stomach contents, is often associated with advancing age [11, 12]. Digestive tract disorders become more common as people get older, resulting in anatomical and functional abnormalities in the gastrointestinal system. In the basal one-third of the mucosa, partial shrinkage of gastric glands is replaced by increased connective tissue [13]. Atrophy and metaplasia of gastric mucosa are premalignant conditions [14, 15].

The study aimed to analyze the gastric stem cell population in different age groups, using Ki-67 immunohistochemistry as a method for their detection.

## MATERIALS AND METHODS

### *Animals*

A total of 21 adult male albino rats, with bodyweight ranging from 100 to 400 g, were used in this study. The rats were obtained from the Animal Care Centre, College of Medicine, King Saud University. The rats were distributed into 3 age groups, each consisting of 7 rats: Group I; Juvenile (3-6 weeks), Group II; Adult (3-6 months), and Group III; Old (9-12 months). After an acclimatization period of one week under standard conditions, all animals were euthanized. The stomach was excised, opened, cleaned, and flushed with normal saline to clean its interior, then fixed and processed to paraffin sections.

### *Histology*

Hematoxylin and eosin (H&E) staining was used to detect any histological differences in the wall of the stomach with special reference to the gastric mucosa.

### *Immunohistochemistry*

Sections were deparaffinized and rehydrated. For antigen unmasking, the sections were immersed in boiling 0.01 M sodium citrate buffer solution (pH 6.0). The endogenous peroxidase activity was quenched by peroxidase quench, and then the sections were incubated in the diluted primary antibody (Ki-67, rabbit monoclonal primary antibody ROCHE, Ventana company) for one hour at room temperature, while the negative control sections were incubated in the washing buffer only. Then, they were incubated in a biotinylated secondary antibody followed by an avidin-biotin (AB) reagent. To demonstrate the antigen-antibody reaction, the sections were incubated in substrate chromogen, followed by counterstaining with Harris hematoxylin, then dehydration, clearing, and mounting.

### *Image analysis*

High-resolution whole-slide digital scans of all anti-Ki-67-immunostained glass slides were created with a ScanScope scanner (Aperio Technologies, Inc.). The digital slide images were viewed and analyzed using Aperio's viewing and image analysis tools. In each section, five fields of a fixed area of 0.31  $\mu\text{m}^2$  were randomly selected. The nuclear analysis algorithm (Aperio Technologies, Inc.) was then applied to quantify nuclear staining and intensity. The algorithm generated a markup image highlighting the detected nuclei which were color-coded according to their classification. The stained nuclei were color-coded in the following manner, according to the intensity of the staining: Blue, 0; Yellow, 1+; Orange, 2+; Red, 3+. Output results included percentage positive nuclei (0.0-100.0%), intensity score (no staining, 0; weak staining, 1+; moderate staining, 2+; strong staining, 3+), percentages of 0, 1+, 2+ and 3+ nuclei, among other statistical measurements.

### *Statistical methods*

The percentage of positive nuclei was subjected to statistical analysis using IBM SPSS Statistics version 22. Analysis of variance (ANOVA) was used for overall comparison between age groups, followed by Bonferroni post-hoc test for pairwise comparisons. Differences were considered significant when *P* was equal to or less than 0.05.

## RESULTS AND DISCUSSION

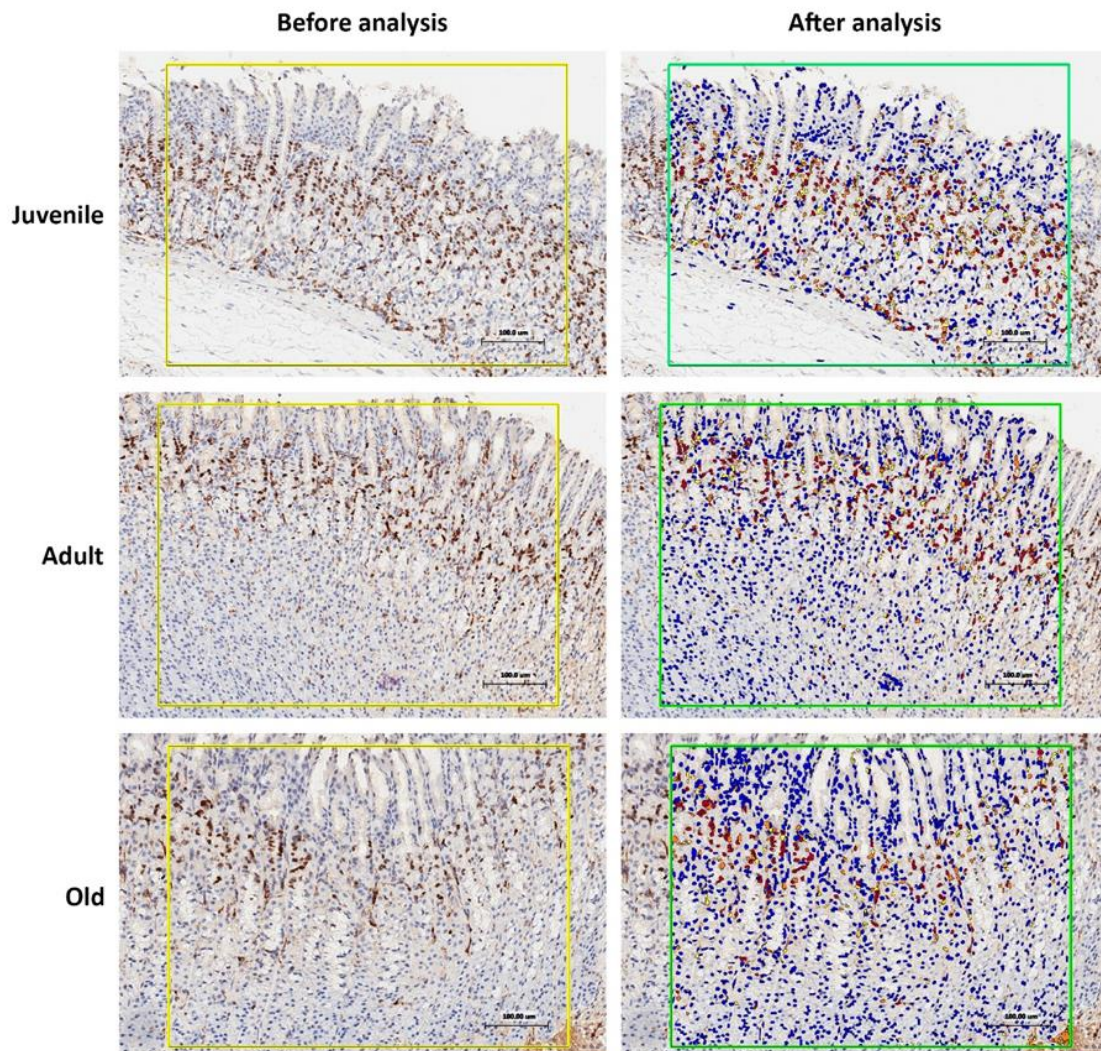
*Stem cells visualization and localization*

The thickness of the mucosal glandular area was much thinner in the Juvenile group than in the Adult group. Stem cells in the gastric glands could not be discerned in H&E-stained slides. They were visualized by Ki-67 immunostaining. They were located mostly in the necks, interspersed among the mucous neck cells, in the isthmus, and the base of the pits of the glands. The staining was predominantly nuclear with varying intensities (Figure 1).

*Image analysis*

Statistical analysis of the data obtained from image analysis revealed that the Ki-67 nuclear staining mean intensity score was slightly higher in the Adult group ( $3 \pm 0.00$ ) than in the Juvenile and Old groups ( $2.6 \pm 0.55$  and  $2.4 \pm 0.55$ , respectively), with no significant differences (Table 1, Figures 1 and 2).

Statistical analysis also showed significantly fewer stem cells (as indicated by the percent Ki-67 positive nuclei) in both the Adult and Old age groups than in the Juvenile group ( $p = 0.04$  and  $0.001$ , respectively). The Old group also showed fewer stem cells than the Adult group, but the difference was not statistically significant ( $p = 0.246$ ) (Table 1, Figures 1 and 2).

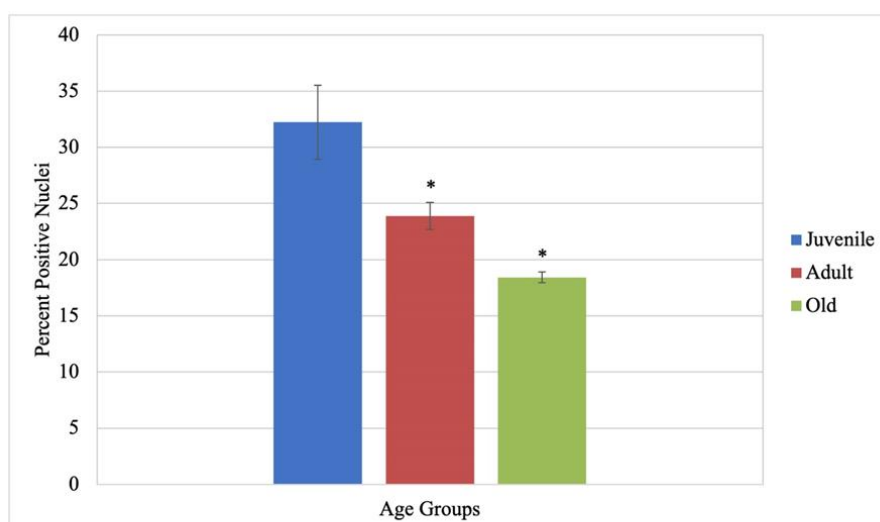


**Figure 1.** Representative images of Ki-67 immunostained sections from the three studied groups before and after nuclear image analysis. After running the nuclear algorithm, the stained nuclei are color-coded in the following manner, according to the intensity of the staining: Blue, 0; Yellow, 1+; Orange, 2+; Red, 3+. In these particular images, the intensity score was 2, 3, and 2, and the percent positive nuclei was 37.31, 23.77, and 18.18 for the Juvenile, Adult, and Old-age groups, respectively. Scale bars = 100  $\mu$ m.

**Table 1.** Ki-67 nuclear staining mean intensity score and percent Ki-67 positive nuclei (mean  $\pm$  SE) in the studied age groups.

	Juvenile	Adult	Old
<b>Intensity score</b>	2.6 $\pm$ 0.55	3 $\pm$ 0.00	2.4 $\pm$ 0.55
<i>P1</i>		0.548	1.000
<i>P2</i>	0.548		0.166
<b>Percent positive nuclei</b>	32.23 $\pm$ 3.28	23.88 $\pm$ 1.20	18.42 $\pm$ 0.48
<i>P1</i>		0.04*	0.001*
<i>P2</i>	0.04*		0.246

SE standard error

\* Difference is significant ( $p \leq 0.05$ ).*P1* compared to Juvenile.*P2* compared to Adult.\* Significant ( $P \leq 0.05$ ) compared to Juvenile group.**Figure 2.** Percent Ki-67 positive nuclei (mean  $\pm$  SE) in the studied age groups.

Most of the GI tract is normally established at the time of birth. However, some growth in structure and function occurs postnatally. Maturation of function varies by animal, with dietary changes being the primary driver of functional changes [6].

Normally, the gastric mucosal epithelium is continually renewed [16]. As a result, the regenerative capacity of the stomach lining epithelium requires gastric epithelial stem cells. These are highly proliferating cells with the potential to differentiate and give rise to all types of gastric mucosal surface and glandular cells, thus maintaining the lining of the stomach [17].

In this study, the Adult and Old age groups had significantly fewer stem cells (as measured by the percent Ki-67 positive nuclei) than the Juvenile group. There were also fewer stem cells in the Old group than in the Adult group. The thickness of the mucosal glandular area was much thinner in the Juvenile group than in the Adult group. This could be attributed to the increase in the number of glandular sections and oxyntic and peptic cells in the adult stomach [6].

The Ki-67 antigen is a protein expressed in the nucleus by the MKI67 gene in humans and is linked to cellular proliferation [18]. It is also linked to the transcription of ribosomal RNA. Inactivation of the antigen Ki-67 causes ribosomal RNA production to be inhibited [19]. The Ki-67 protein is a cell proliferation marker that can be utilized in immunohistochemistry [20].

Studies performed in animal models revealed that gastric stem cells respond to mucosal damage and inflammation [21-23]. The development of gastric stem cell research is paving the way to better prevention and treatment of gastric disorders [24]. In this study, the mean intensity score of Ki-67 nuclear staining was slightly higher in the Adult group than in the Juvenile and Old groups, which explains why rat aging is associated with some gastric mucosal atrophy. The increase in mucosal thickness observed in old age was explained by the increase in the

amount of connective tissue around small vessels in the subepithelial layer [25]. These changes in old age may obstruct oxygen and nutrient transport to the epithelial cells, leading to some atrophy of the peptic and oxyntic cells with replacement with fibrous connective tissue. Alterations in aging-related stomach secretory activities could be explained by these structural changes [26].

In agreement with our findings, the slow healing of peptic ulcer in rats as they get older could be linked to diminished epithelial cell proliferation and angiogenic activity [27]. Understanding the effect of age on the GI tract could lead to improvements in geriatric medication prescriptions, reducing their side effects, and thus encouraging the elderly to comply with their medical management plans [28].

## CONCLUSION

In conclusion, we found that the gastric stem cell population decreases with age. This finding could be therapeutically important, especially in the medical treatment of older patients. More research is needed to elucidate the implication of gastric stem cells in various gastric disorders and to develop innovative techniques to prevent gastric cancer.

**ACKNOWLEDGMENTS :** None

**CONFLICT OF INTEREST :** None

**FINANCIAL SUPPORT :** None

**ETHICS STATEMENT :** All applicable international, national, and institutional guidelines for the care and use of animals were followed.

## REFERENCES

1. Hunt RH, Camilleri M, Crowe SE, El-Omar EM, Fox JG, Kuipers EJ, et al. The stomach in health and disease. *Gut*. 2015;64(10):1650-68. doi:10.1136/gutjnl-2014-307595. Available from: <https://www.ncbi.nlm.nih.gov/pubmed/26342014>.
2. Thibodeau GA, Patton KT. *Anatomy and Physiology*. 2nd ed. Mosby-Year Book, St. Louis, MO; 1993.
3. Baintner K. *Intestinal Absorption of Macromolecules and Immune Transmission from Mother to Young*. 1st ed. CRC Press, Ins Florida; 1986.
4. Deren JS. Development of structure and function in the fetal and newborn stomach. *Am J Clin Nutr*. 1971;24(1):144-59. doi:10.1093/ajcn/24.1.144. Available from: <https://www.ncbi.nlm.nih.gov/pubmed/4923462>.
5. De Zwart LL, Haenen HE, Versantvoort CH, Wolterink G, Van Engelen JG, Sips AJ. Role of biokinetics in risk assessment of drugs and chemicals in children. *Regul Toxicol Pharmacol*. 2004;39(3):282-309. doi:10.1016/j.yrtph.2004.02.006. Available from: <https://www.ncbi.nlm.nih.gov/pubmed/15135209>.
6. Walthall K, Cappon GD, Hurtt ME, Zoetis T. Postnatal development of the gastrointestinal system: a species comparison. *Birth Defects Res B Dev Reprod Toxicol*. 2005;74(2):132-56. doi:10.1002/bdrb.20040. Available from: <https://www.ncbi.nlm.nih.gov/pubmed/15834902>.
7. Henning SJ. Postnatal development: coordination of feeding, digestion, and metabolism. *Am J Physiol*. 1981;241(3):G199-214. doi:10.1152/ajpgi.1981.241.3.G199. Available from: <https://www.ncbi.nlm.nih.gov/pubmed/7025659>.
8. Buddington RK. Nutrition and ontogenetic development of the intestine. *Can J Physiol Pharmacol*. 1994;72(3):251-9. doi:10.1139/y94-039. Available from: <https://www.ncbi.nlm.nih.gov/pubmed/8069771>.
9. Drozdowski L, Thomson AB. Aging and the intestine. *World J Gastroenterol*. 2006;12(47):7578-84. doi:10.3748/wjg.v12.i47.7578. Available from: <https://pubmed.ncbi.nlm.nih.gov/17171784>.
10. Gariballa SE, Sinclair AJ. Nutrition, aging, and ill-health. *Br J Nutr*. 1998;80(1):7-23. doi:10.1017/s000711459800172x. Available from: <https://pubmed.ncbi.nlm.nih.gov/9797639>.
11. Saber A. Perioperative Care of Elderly Surgical Patients. *Am Med J*. 2013;4(1):63. doi:10.3844/amjsp.2013.63.77.

12. Soenen S, Rayner CK, Horowitz M, Jones KL. Gastric Emptying in the Elderly. *Clin Geriatr Med.* 2015;31(3):339-53. doi:10.1016/j.cger.2015.04.003. Available from: <https://www.ncbi.nlm.nih.gov/pubmed/26195094>.
13. Tarnawski AS, Ahluwalia A, Jones MK. Increased susceptibility of aging gastric mucosa to injury: the mechanisms and clinical implications. *World J Gastroenterol.* 2014;20(16):4467-82. doi:10.3748/wjg.v20.i16.4467. Available from: <https://www.ncbi.nlm.nih.gov/pubmed/24782600>.
14. Correa P. Human gastric carcinogenesis: a multistep and multifactorial process--First American Cancer Society Award Lecture on Cancer Epidemiology and Prevention. *Cancer Res.* 1992;52(24):6735-40. Available from: <https://www.ncbi.nlm.nih.gov/pubmed/1458460>.
15. Annibale B, Esposito G, Lahner E. A current clinical overview of atrophic gastritis. *Expert Rev Gastroenterol Hepatol.* 2020;14(2):93-102. doi:10.1080/17474124.2020.1718491. Available from: <https://www.ncbi.nlm.nih.gov/pubmed/31951768>.
16. Karam SM, Leblond CP. Dynamics of epithelial cells in the corpus of the mouse stomach. II. Outward migration of pit cells. *Anat Rec.* 1993;236(2):280-96. doi:10.1002/ar.1092360203. Available from: <https://www.ncbi.nlm.nih.gov/pubmed/8338233>.
17. Mills JC, Shivdasani RA. Gastric epithelial stem cells. *Gastroenterology.* 2011;140(2):412-24. doi:10.1053/j.gastro.2010.12.001. Available from: <https://pubmed.ncbi.nlm.nih.gov/21144849>.
18. Bullwinkel J, Baron-Lühr B, Lüdemann A, Wohlenberg C, Gerdes J, Scholzen T. Ki-67 protein is associated with ribosomal RNA transcription in quiescent and proliferating cells. *J Cell Physiol.* 2006;206(3):624-35. doi:10.1002/jcp.20494. Available from: <https://www.ncbi.nlm.nih.gov/pubmed/16206250>.
19. Rahmzadeh R, Hüttmann G, Gerdes J, Scholzen T. Chromophore-assisted light inactivation of pKi-67 leads to inhibition of ribosomal RNA synthesis. *Cell Prolif.* 2007;40(3):422-30. doi:10.1111/j.1365-2184.2007.00433.x. Available from: <https://www.ncbi.nlm.nih.gov/pubmed/17531085>.
20. Scholzen T, Gerdes J. The Ki-67 protein: from the known and the unknown. *J Cell Physiol.* 2000;182(3):311-22. doi:10.1002/(SICI)1097-4652(200003)182:3<311::AID-JCP1>3.0.CO;2-9. Available from: <https://www.ncbi.nlm.nih.gov/pubmed/10653597>.
21. Arnold K, Sarkar A, Yram MA, Polo JM, Bronson R, Sengupta S, et al. Sox2(+) adult stem and progenitor cells are important for tissue regeneration and survival of mice. *Cell Stem Cell.* 2011;9(4):317-29. doi:10.1016/j.stem.2011.09.001. Available from: <https://www.ncbi.nlm.nih.gov/pubmed/21982232>.
22. Choi E, Lantz TL, Vlacich G, Keeley TM, Samuelson LC, Coffey RJ, et al. Lrig1+ gastric isthmal progenitor cells restore normal gastric lineage cells during damage recovery in adult mouse stomach. *Gut.* 2018;67(9):1595-605. doi:10.1136/gutjnl-2017-313874. Available from: <https://www.ncbi.nlm.nih.gov/pubmed/28814482>.
23. Nienhüser H, Kim W, Malagola E, Ruan T, Valenti G, Middelhoff M, et al. Mist1+ gastric isthmus stem cells are regulated by Wnt5a and expand in response to injury and inflammation in mice. *Gut.* 2021;70(4):654-65. doi:10.1136/gutjnl-2020-320742. Available from: <https://www.ncbi.nlm.nih.gov/pubmed/32709613>.
24. Xiao S, Zhou L. Gastric Stem Cells: Physiological and Pathological Perspectives. *Front Cell Dev Biol.* 2020;8:571536. doi:10.3389/fcell.2020.571536. Available from: <https://www.ncbi.nlm.nih.gov/pubmed/33043003>.
25. Hollander D, Tarnawski A, Stachura J, Gergely H. Morphologic changes in gastric mucosa of aging rats. *Dig Dis Sci.* 1989;34(11):1692-700. doi:10.1007/BF01540046. Available from: <https://www.ncbi.nlm.nih.gov/pubmed/2582982>.
26. Krasinski SD, Russell RM, Samloff IM, Jacob RA, Dallal GE, McGandy RB, et al. Fundic atrophic gastritis in an elderly population. Effect on hemoglobin and several serum nutritional indicators. *J Am Geriatr Soc.* 1986;34(11):800-6. doi:10.1111/j.1532-5415.1986.tb03985.x. Available from: <https://www.ncbi.nlm.nih.gov/pubmed/3771980>.
27. Ajayi AF, Olaleye SB. Immunohistochemical Studies of Age-Related Changes in Cell Proliferation and Angiogenesis during the Healing of Acetic Acid-Induced Gastric Ulcers in Rats. *Sci World J.* 2020;2020:3506207. doi:10.1155/2020/3506207. Available from: <https://www.ncbi.nlm.nih.gov/pubmed/32549798>.
28. Aly S, Emad KB. Age-related gastric changes. *J Surg.* 2016;4(2):20-6.