



Original Article

ISSN : 2277-3657
CODEN(USA) : IJPRPM

A Prospective Study on Helical Computed Tomography in the Assessment of Gastrointestinal Lesions in HIV Patients

Devara Anil Kashi Vishnuvardhan¹, Kallepally Anil Kumar^{1*}, Merugu Chandhana², Sonica Sharma³, Vernekar Avinash⁴

¹Department of Radiodiagnosis, Maharajah's Institute of Medical Sciences (MIMS), Nellimarla, Vizianagaram district-535217, Andhra Pradesh, India.

²Department of Endocrinology, Jawaharlal Institute of Postgraduate Medical Education and Research (JIPMER) Campus Rd, Gorimedu, Dhanvantari Nagar, Puducherry-605006, India.

³Department of Radiodiagnosis, GITAM Institute of Medical Sciences and Research, GITAM (Deemed to be University), Visakhapatnam-530045, Andhra Pradesh, India.

⁴Specialist Radiology, Burjeel Day Surgery Centre, Abu Dhabi, UAE.

*Email: anilkradio@gmail.com

ABSTRACT

Helical computed tomography (HCT) helps early detection of gastrointestinal involvement and categorizes the lesions into infective and neoplastic etiologies. A quick institution of presumptive treatment reduces morbidity, hospital stay, etc. The study deals with the spectrum and frequency of gastrointestinal lesions in the abdomen of Human immunodeficiency virus (HIV) positive patients and correlates the gastrointestinal lesions with CD₄ count. A total of 40 patients with a known history of HIV infection and a recent CD₄ count were included in the study. After correlating the computed tomography (CT) scans with clinical history, available hematological, biochemical, histopathological, serological investigations, etc., the lesions were classified into infective and neoplastic lesions. The yield of abnormal abdominal computed tomography findings was 95%, and the remaining 5% were normal. Neoplastic lesions occur at very low (<CD₄ count 100 cells/ μ L) and narrow CD₄ count range of 50 – 100 cells/ μ L. The occurrence of infective lesions was at relatively higher CD₄ count than neoplastic lesions, but CD₄ count < 300 cells/ μ L and the narrow CD₄ count ranges for multiple liver abscesses was 34 - 200 cells/ μ L, multiple splenic abscesses were 6 – 300 cells/ μ L, infective slight bowel wall thickening was 35 - 250 cells/ μ L. Helical computed tomography is a ray of hope for the plight of HIV-positive patients in India. It serves as the most rapid, cost-effective, early, and efficient means of assessing the extent of gastrointestinal involvement in the abdomen of HIV-positive patients.

Key words: HIV, Gastrointestinal lesions, Neoplastic lesions, CD₄ count, Helical computed tomography, Infective lesions

INTRODUCTION

The hallmark of Human immunodeficiency virus (HIV) disease is an intense immunodeficiency disease primarily due to progressive quantitative and qualitative deficiency of the subset of T- Lymphocytes called CD₄ helper T-cells or inducer T-cells [1]. According to the current Centre for disease control (CDC), the classification system comprises HIV-infected adolescents and adults who categorize persons based on clinical conditions associated with HIV infection and CD₄ lymphocyte counts. The system is based on three ranges of CD₄ count and three clinical categories (A, B, C), consisting of various clinical conditions. Three ranges of CD₄ count include cells/ μ L >500/ μ L, 200 - 499/ μ L and < 200/ μ L [2-6].

The importance of the gastrointestinal system in this grand scheme of acquired immunodeficiency syndrome cannot be underestimated as it is the primary surface where contact between man and environment takes place and is many times larger than the skin [7]. The gastrointestinal tract is the portal of entry for HIV infections in a large number of cases. There are various estimates of the prevalence of gastrointestinal complaints in patients with human immunodeficiency virus ranging from 30 to 90%. In India, more than 90% of patients have gastrointestinal complaints. A wide variety of investigations are carried out to evaluate gastrointestinal involvement like blood profile, barium studies, ultrasonography, computed tomography, magnetic resonance imaging, nuclear scans, etc. Helical computed tomography (HCT) defines the same organ of involvement, morphology, and spectrum of lesions which explain the symptoms and with clinical and laboratory investigations (CD4 count). Helical computed tomography is a single, rapid, cost-effective investigation, which reveals the entire spectrum of gastrointestinal Involvement [8-12].

Rapid, early detection of gastrointestinal involvement and categorizing the lesions into infective and neoplastic etiologies with a quick institution of presumptive treatment reduces the morbidity, hospital stay and thus for better health of Individual contributing to increased work hours in young adult and add to the gross domestic product (GDP) and also improves the GDP. It helps detect intraabdominal complications arising from the treatment of Acquired immune deficiency syndrome (AIDS). HCT guided lymph node biopsies and liver abscess drainage act as minimally invasive procedures and play an essential part in managing HIV-positive patients. Post-treatment HCT may be used to assess the resolution or progression of disease not only gaining new insights into the microbes and the immune system interaction, pathologic process, but we are also changing our views about the unparalleled role of the radiologist in describing or pinpointing the gastrointestinal lesions and with computed tomography (CT) guided lymph node biopsies, liver abscess drainage, etc. play a prominent part in the management of human immunodeficiency virus-positive patients [13-16].

The present study aimed to determine the spectrum and frequency of gastrointestinal lesions in the abdomen of Human immunodeficiency virus-positive patients and correlate the gastrointestinal lesions with CD4 count. The study also focused on demonstrating that computed tomography reliably reveals the extent and severity of gastrointestinal involvement in the abdomen of Human immunodeficiency virus-positive patients and enhances computed tomography's value in classifying the gastrointestinal lesions into infective and neoplastic etiologies.

MATERIALS AND METHODS

Study population

Institutional Ethics Committee clearance approval (No.MIMS/Admn./Ethics/approval/IEC-10/2018) was obtained before the start of the study. Each participant has explained the details of the study and informed consent was obtained. A total of 40 patients with a known history of HIV infection and recent CD₄ count were admitted to the hospital with complaints of Nausea, fever, vomiting, diarrhea, weight loss, jaundice, lump in the abdomen, and gastrointestinal (upper and lower) bleeding referred from almost all departments mainly medicine, surgery, obstetrics, and gynecology and were evaluated with Helical Computed Tomography.

Patient preparation

History and physical examination of all patients were systematically carried out. All patients were required to be Nil by mouth for 5-6 hrs before the examination. Oral contrast through 2 ampoules of 60% Iodinated contrast is mixed in 1 ½ liter of plain water. The patient is made to drink 500ml at half-hourly intervals with 100 – 200ml of contrast to be given on the CT table for adequate stomach distension. Tampons were inserted into the vagina of married female patients

Patient position

The patient was placed supine on the computed tomography table. The Head was immobilized with a headrest. Hands were folded above the shoulder around the head. Rectal contrast was given- 1 ampoule of 76% iodinated contrast in 250 – 300 ml. of water if needed to distend the rectum-appropriate positioning with the help of a laser marker concerning the field of interest.

Topogram

A scout topogram was obtained from just above domes of the diaphragm up to the symphysis pubis (Region of interest).

Scan parameters

SIEMENS SOMATOM plus 4A whole body spiral CT scanner with 220 MA (milliamperes) / 140 (KV) Kilovoltage was used in the present study. In pre-contrast contiguous sequential scans and slices of 10mm thickness were taken. Thin sections were taken according to the need. In post intravenous contrast, a bolus of 100 ccs of 76% iodinated contrast was injected at 1.7 to 2ml / sec via a pressure injector. The parameters also include the scan delay was 46-50 seconds, collimation 5mm, table feed 5mm, reconstruction interval 5mm, phases of acquisition in single-phase or dual-phase, if needed, region scanned from just above domes of the diaphragm up to the symphysis pubis, multiplanar reconstruction (MPR) (post-processing) was done wherever needed, delayed scans were obtained whenever it was deemed necessary, tailoring the examination to the working clinical diagnosis by optimizing constituent factors (e.g. timing of the acquisition, oral contrast used and rate of contrast material administration, collimation, table feed) and scan time takes 20 minutes which include taking in and taking out.

A systematic approach was adopted while evaluating scans. All the scans were evaluated to localize the lesions, define the extent, identify the site of origin, characterize the nature of lesions, locate the vascular structures concerning the lesions, and determine their involvement and associated lymphadenopathy. After correlating with clinical history, available hematological, biochemical, histopathological, serological investigations, response to therapy and follow up, etc., the lesions were classified into infective and neoplastic lesions.

The data was statistically represented in the form of percentages for all the categorical variables.

RESULTS AND DISCUSSION

Of the total, 40 subjects of known HIV-positive status underwent computed tomographic evaluation of the abdomen for gastrointestinal symptoms for 30 months.

Out of 40 cases reported, males 27 (67.5%) were more affected than females 13 (32.5%). Based on the age-wise categorization of patients, more numbers were recorded in the age group 21-40 years 30 (75%) whereas two cases (5%) were reported < 20 years and eight cases (20%) from 41-60 years. The yield of abnormal abdominal computed tomography findings was 95% (38/40 cases), and the remaining 5% were normal.

From **Table 1**, it was found that the focal lesions in the liver were found to be hypodense. A single lesion in the liver showed (Rim/peripheral) enhancement. Multiple lesions in the liver were non-enhancing. All focal lesions in the spleen were found to be hypodense. Single lesions were not found in the spleen. All the lesions in the spleen were multiple lesions, which were non-enhancing. Only one single lesion was seen in the pancreas with (peripheral) rim enhancement. (Pseudocyst of the pancreas). From **Table 2**, it was found that, in the ilio-caecal junction, the small-bowel was more commonly involved than the large bowel. The small bowel was usually involved as circumferential long segment thickening <1.5 cm, and all cases were found to be infective. In one case, the large bowel showed circumferential short segment thickening <1.5 cm, which became infective. Another case showed circumferential long segment thickening >1.5 cm, which turned out to be neoplastic (lymphoma). Four cases showed circumferential short segment thickening <1.5 cm. One case showed circumferential long segment thickening <1.5 cm. One case showed focal, long segment thickening >1.5 cm. All cases were found to be infective. From **Table 3**, it was revealed that abdominal lymphadenopathy was seen in 55% of cases. Hypodense, Non-enhancing, bulky, extensive mesenteric, and retroperitoneal lymphadenopathy was consistent with neoplastic etiology seen in 5% of cases. Hypodense, rim enhancing, homogeneously enhancing, small to large mesenteric, and retroperitoneal lymphadenopathy was consistent with infective etiology seen in 50% of cases. Only abdominal lymphadenopathy and no other lesion elsewhere (12.5%). Abdominal lymphadenopathy with multiple splenic hypodense lesions (abscesses) (25%). The yield of abnormal CT findings in the abdomen ranges as 95% in 38 subjects, followed by multifocal areas of involvement in the abdomen 14 (35%) and few subjects 9(22.5%) showed biliary tract involvement, ascites, mesenteric abscess, and two subjects (5%) showed no obvious abnormality findings. **Table 4** showed the correlation of abnormal abdominal computed tomography findings with CD4 count. The occurrence of neoplastic lesions like multiple liver deposits, multiple splenic deposits, neoplastic abdominal lymphadenopathy, neoplastic bowel wall thickening occur at very low (<CD4 count 100 cells/ μ L) and narrow CD4 count range of 50 – 100 cells/ μ L. The occurrence of infective lesions multiple liver abscesses, multiple splenic abscesses, infective bowel wall thickening at relatively higher CD4 count than neoplastic lesions, but CD4 count < 300 cells/ μ L and the narrow CD4 count ranges for multiple liver abscesses was 34 - 200 cells/ μ L, multiple splenic abscesses were 6 – 300 cells/ μ L, infective (small) bowel wall thickening was 35 - 250 cells/ μ L. **Figures 1a and b** represents the graphical correlation of CT lesions of the abdomen in the

symptomatic phase with relation to CD₄ count, even in the neoplastic stages. **Figures 2a-c** to **Figures 3a-c** describes the computed tomographic features of common abnormal abdominal findings. From the results it was found that hepatomegaly, splenomegaly, abdominal lymphadenopathy (infective), and biliary tract involvement occur over a wide CD₄ count range. Hence there appears to be no specific relationship with CD₄ count. The abdominal viscus is involved diffusely or focally. Diffuse involvement causes organomegaly, i.e., hepatomegaly, splenomegaly. etc. Focal involvement can be a single lesion involving the solid viscera that can be infective or neoplastic. Multiple lesions involving the solid viscera can be infective or neoplastic. But the image morphology of the lesions like the location, size, margins, density, and enhancement characteristics with clinical profile help in distinguishing infective from neoplastic lesions. It was also revealed that neoplastic abdominal computed tomographic findings consistently occur at very low CD₄ counts, thus may help in establishing a definite correlation between neoplastic computed tomographic lesions and CD₄ counts. The abnormal abdominal computed tomographic findings of infective etiology consistently occurred at low CD₄ count ranges and thus may help in establishing a correlation between these findings and CD₄ counts.

Table 1. Spectrum and frequency of lesions in solid viscera of subjects

	Organo-Megaly	Lesions		Density Hypo-dense	Rim		Infective	Neoplastic
		Multiple	Single		Enhancing	Non-Enhancing		
Liver	25/40	4/40	1/40	5/40	1/40	4/40	4/40	1/40
(%)	62%	10%	2.5%	12.5%	2.5%	10%	10%	2.5%
Spleen	22/40	16/40	0	16/40	0	16/40	15/40	1/40
(%)	55%	40%	0%	40%	0%	40%	37%	2.5%
Pancreas	-	-	1/40	1/40	1/40	-	-	-
(%)	-	-	2.5%	2.5%	2.5%	-	-	-

Table 2. Spectrum and frequency of lesions in the bowel of subjects

Bowel	Thickness		Thickening				Infective	Neoplastic
	>1.5cm	<1.5cm	Focal	Circumferential	Long segment > 10cm	Short segment <10cm		
Small	-	5/40	-	5/40	5/40	-	5/40	-
%	-	12.5	-	12.5	12.5	-	12.5	-
Large	1/40	1/40	-	2/40	1/40	1/40	1/40	1/40
%	2.5	2.5	-	5	2.5	2.5	2.5	2.5
Icregion	1/40	5/40	1/40	5/40	2/40	4/40	6/40	-
%	2.5	12.5	2.5	12.5	5	10	15	-

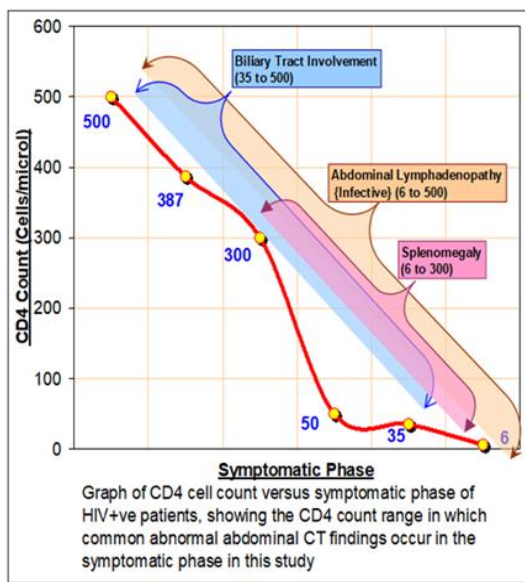
Table 3. Computed tomographic characteristics of abdominal lymphadenopathy

		Abdominal lymphadenopathy								Neoplastic
Small	Large	NECT		CECT			REGION			
		Iso-dense	Hypo-dense	Homogenous	Non enhancing	Rim	Mesenteric	Retro-peritoneal	Infection	
19	3	17/40	5/40	10/40	1/40	11/40	17/40	17/40	20/40	2/40
47.5%	12.5%	25%	2.5%	27.5%	2.5%	27.5%	42.5%	42.5%	50%	5%

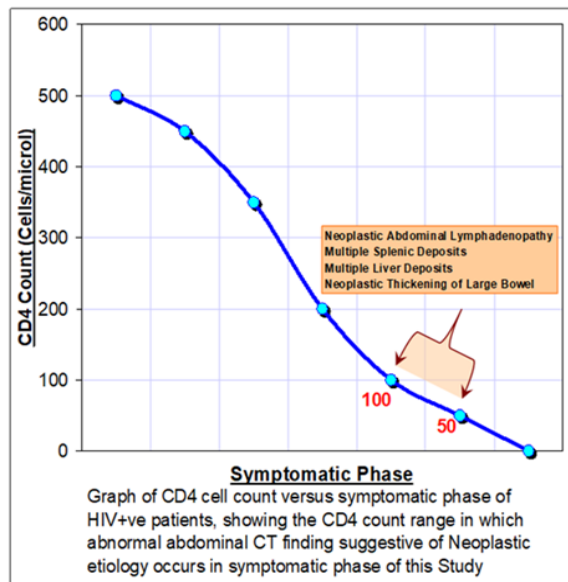
Table 4. Correlation of abnormal abdominal (CT) computed tomographic findings with CD₄ count

CT Findings	CD 4 Count Range (Cells / μ L)
- Hepatomegaly	6 – 387
Single Liver Lesion	441
Multiple Liver Lesions s/o Multiple Liver abscesses (Infective)	34 – 200
Multiple Liver Lesions s/o Neoplastic deposits	50 – 100
- Splenomegaly	6 – 300

Multiple splenic lesions S/o. Multiple splenic abscesses (infective)	6 – 300
Multiple splenic lesions S/o. Neoplastic deposits	50 – 100
- Small bowel involvement of infective Etiology	35 – 250
Large bowel involvement of infective etiology	149
Large bowel involvement of Neoplastic etiology	100
IC region involvement of infective etiology	42 – 350
- Abdominal Lymphadenopathy	6 – 500
Infective	6 - 500
Neoplastic	50 – 100
- Billiary tract involvement	35 – 500
- Ascites	100, 149
- Mesentric abscess	250
- Multifocal areas of involvement in the abdomen	6 – 250
- No obvious abnormality detected	16, 500

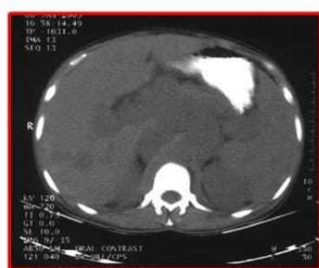

a)



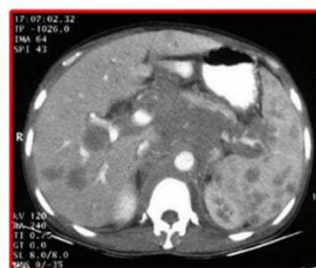b)

Figure 1. a) Graphical correlation of CT lesions of the abdomen in HIV patients with CD₄ counts and symptomatic phase of patients. b) Graphical correlation of CT lesions of abdomen suggestive of neoplastic etiology in HIV patients with CD₄ counts and symptomatic phase of the patient.



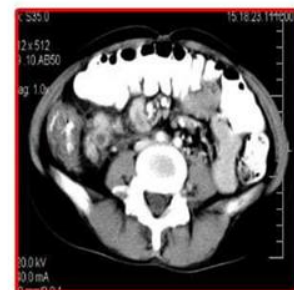NECT

a)



CECT

b)



c)

Figure 2. a, b) NECT AND CECT: Multiple lymphomatous deposits in liver and spleen with bulky abdominal lymphadenopathy. c) CECT Showing iliocecal thickening with rim enhancing mesenteric lymphadenopathy-iliocecal tuberculosis

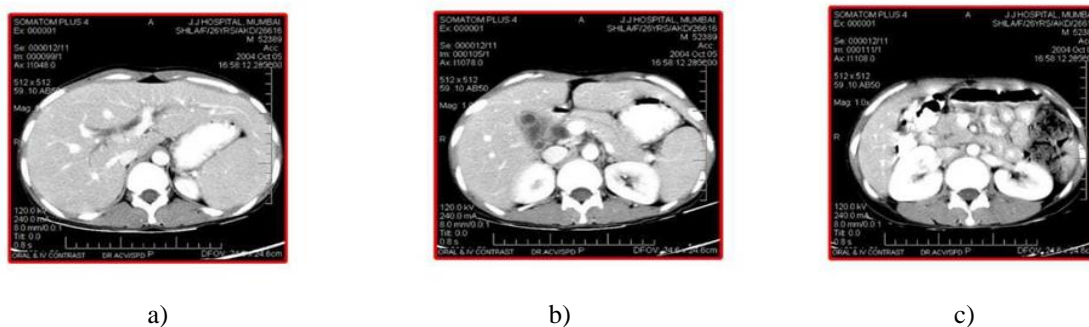


Figure 3. a-c) CECT: Showing dilated biliary tree and smooth tapering of dilated CBD with ampullary stenosis-HIV cholangiopathy

Many investigations are available to evaluate gastrointestinal involvement, but computed tomography has improved the yield and defined the extent of abnormal abdominal gastrointestinal lesions among human immunodeficiency virus-positive patients. In the present study, the percentage of abnormal CT findings was higher 95% than the similar study done by Knollmann *et al.* (1995, 1997) [17-19] in which out of 339 patients, 278 (82%) showed abnormal abdominal findings on CT.

In the current study, hepatomegaly (62%), splenomegaly (55%), multiple hypodense lesions in the liver (10%) multiple hypodense lesions in the spleen (40%) were found to be higher. The results coincide with Knollmann *et al.* (1995, 1997) [17-19] and Radin *et al.* (1995), [20] who reported hepatomegaly (38.6%), splenomegaly (23.9%), and low-attenuation lesions in the liver (19.3%) or spleen (21.2%) in a total of 259 cases. The reasons might be the small sample size, insufficient nourishment and immunity in the Indian population, and lack of microbe-free environment/ proper hygiene. The abdominal lymphadenopathy in 55% of cases was lower than the study done by Radin *et al.* (1995) [20], which reported lymph-node enlargement in 61% of cases. The abdominal lymphadenopathy in 55% of cases was higher than the study done by Knollmann *et al.* (1995, 1997) [17-19], which reported lymphadenopathy in 32% of cases. In the current study, the occurrence of neoplastic lesions like multiple liver deposits, multiple splenic deposits, neoplastic abdominal lymphadenopathy, neoplastic bowel wall thickening occur at very low (<CD4 count 100 cells/ μ L) and narrow CD4 count range of 50 – 100 cells/ μ L. The occurrence of infective lesions multiple liver abscesses, multiple splenic abscesses, infective bowel wall thickening at relatively higher CD4 count than neoplastic lesions, but CD4 count < 300 cells/ μ L and the narrow CD4 count ranges for multiple liver abscesses was 34 - 200 cells/ μ L, multiple splenic abscesses were 6 – 300 cells/ μ L, infective (slight) bowel wall thickening was 35 - 250 cells/ μ L which were in accordance to the results of previous studies [6, 20-24] So, with appropriate image morphology of the lesions, clinical profile, and correlation with CD4 count, we can narrow down the diagnosis to infective and neoplastic etiologies, which in turn leads to diagnosis and hence presumptive treatment/quick management (before the histopathological/microbiologic confirmation), less morbidity especially in our country where the HIV patients are poor, non-affording and where histopathological/microbiologic confirmation is rarely resorted to in HIV patients due to various reasons [25, 26]. Multifocal involvement of abdominal viscera was seen in 35% of cases and was seen to occur at lower cd4 count range 6 – 250 cells/micro and was associated with poor prognosis.

This potentially important observation of multifocal areas of involvement of the gastrointestinal system (liver, spleen, bowel, etc.) in most patients with advanced HIV disease (CD4<250 cells/ μ L) vice versa in an unknown case of HIV may act as an important indicator of human immunodeficiency virus infection.

CONCLUSION

Helical computed tomography is the modality of choice for being the rapid, cost-effective method that has revolutionized the imaging of the abdomen in HIV patients revealing the organ of involvement, the spectrum of lesions, the extent of gastrointestinal involvement, and characterizing the lesions into infective/neoplastic lesions. A potentially important conclusion is the existence of multifocal areas of involvement of the gastrointestinal tract (liver, bowel, spleen, etc.) in most patients with advanced HIV disease vice versa in an unknown case of HIV may act as an important indicator of HIV infection and acts as a poor prognostic indicator. With appropriate image morphology of the lesions, clinical profile, and correlation with CD4 count, we can narrow down the diagnosis to infective and neoplastic etiologies which in turn leads to diagnosis and hence quick presumptive management (before the histopathological/microbiologic confirmation) less morbidity - especially in our country where the

HIV patients are poor, non-affording and where histopathological/microbiologic confirmation is rarely resorted to in HIV patients due to various reasons.

ACKNOWLEDGMENTS : None

CONFLICT OF INTEREST : None

FINANCIAL SUPPORT : None

ETHICS STATEMENT : The study was based on the extended work of MD thesis done in the department of Radiology, Grant medical college and Sir J.J. Group of hospitals, Examination of University of Mumbai and MIMS, Vizianagaram. This study was reviewed and approved by The Ethics Committee of the institute.

REFERENCES

1. Zhytnik T, Yermak H, Moskalyova L, Podplota S, Fedorova O, Liapunova V. Socio-psychological aspects of HIV infection prevention among first-year university students as a health-saving factor. *Int J Pharm Res Allied Sci.* 2020;8(1):1-8.
2. Smilack JD. AIDS: etiology, diagnosis, treatment, and prevention. *JAMA.* 1997;278(2):170-1. doi:10.1001/jama.1997.03550020102051
3. Friedland GH. The guide to living with HIV infection: developed at the Johns Hopkins AIDS clinic. *JAMA.* 1992;268(6):737. doi:10.1001/jama.1992.03490060069022
4. Volberding P. AIDS: etiology, diagnosis, treatment, and prevention. *JAMA.* 1989;262(10):1397-8. doi:10.1001/jama.1989.03430100133050
5. Lyerly HK. AIDS: etiology, diagnosis, treatment and prevention. *Ann Surg.* 1986;203(3):334.
6. Sansom H, Seddon B, Padley SP. Clinical utility of abdominal CT scanning in patients with HIV disease. *Clin Radiol.* 1997;52(9):698-703. doi:10.1016/S0009-9260(97)80035-9
7. Bottalico L, Castellaneta F, Charitos IA. From hydrotherapy to the discovery of the gut microbiota: the historical gastrointestinal health concept. *Pharmacophore.* 2020;11(2):82-90.
8. Nyberg DA, Federle MP, Jeffrey RB, Bottles K, Wofsy CB. Abdominal CT findings of disseminated *Mycobacterium avium-intracellulare* in AIDS. *Am J Roentgenol.* 1985;145(1):297-9. doi:10.2214/ajr.145.2.297
9. Jeffrey RB, Nyberg DA, Bottles K, Abrams DI, Federle MP, Wall SD, et al. Abdominal CT in acquired immunodeficiency syndrome. *Am J Roentgenol.* 1986;146(1):7-13. doi:10.2214/ajr.146.1.7
10. Nyberg DA, Jeffrey Jr RB, Federle MP, Bottles K, Abrams DI. AIDS-related lymphomas: evaluation by abdominal CT. *Radiology.* 1986;159(1):59-63. doi:10.1148/radiology.159.1.3952331
11. Jeffrey Jr RB, Goodman PC, Olsen WL, Wall SD. Radiologic imaging of AIDS. *Curr Probl Diagn Radiol.* 1988;17(3):113-7. doi:10.1016/0363-0188(88)90008-4
12. Jones B, Fishman EK. CT of the gut in the immunocompromised host. *Radiol Clin North Am.* 1989;27(4):763-71.
13. Tosch U, Jautzke G, Ruf B, Witt H. Comparison of computerized tomography and pathologic-anatomic findings of the abdomen in HIV infection. *Digitale Bilddiagn.* 1990;10(2):54-8.
14. Malekzadeh S, Widmer L, Salahshour F, Egger B, Ronot M, Thoeny HC. CT-morphologic aspects of the liver in patients with HIV infection. *Aktuelle Radiol.* 1994;4(4):188-91. doi:10.1007/s00261-020-02642-z
15. Chung CJ, Sivit CJ, Rakusan TA, Ellaurie M. Abdominal lymphadenopathy in children with AIDS. *Pediatr AIDS HIV Infect.* 1994;5(5):305-8.
16. Wyatt SH, Fishman K. The acute abdomen in individuals with AIDS. *Radiol Clin North Am.* 1994;32(5):1023-43.
17. Knollmann FD, Adler A, Mäurer J, Grünwald T, Hintze RE, Schedel H, et al. Comparative imaging of HIV associated diseases of the hepatobiliary system in computerized tomography and cholangiography. *Aktuelle Radiol.* 1995;5(4):216-21.
18. Knollmann FD, Grünwald T, Mäurer J, Schedel H, Schröder R, Pegios W, et al. Diagnostic results of abdominal computerized tomography in HIV-infected patients. *Aktuelle Radiol.* 1995;5(6):351-5.
19. Knollmann FD, Grünwald T, Adler A, Mäurer J, Hintze RE, Pohle HD, et al. Intestinal disease in acquired immunodeficiency: evaluation by CT. *Eur Radiol.* 1997;7(9):1419-29.

20. Radin R. HIV infection: analysis in 259 consecutive patients with abnormal abdominal CT findings. *Radiology*. 1995;197(3):712-22. doi:10.1148/radiology.197.3.7480744
21. Balthazar EJ, Noordhoorn M, Megibow AJ, Gordon RB. CT of small-bowel lymphoma in immunocompetent patients and patients with AIDS: comparison of findings. *Am J Roentgenol*. 1997;168(3):675-80. doi:10.2214/ajr.168.3.9057513
22. Knollmann FD, Mäurer J, Grünewald T, Schedel H, Vogl TJ, Pohle HD, et al. Abdominal CT features and survival in acquired immunodeficiency. *Acta Radiol*. 1997;38:970-7. doi:10.1080/02841859709172112
23. Gore RM, Miller FH, Yaghami V. Acquired immunodeficiency syndrome (AIDS) of the abdominal organs: imaging features. *Semin Ultrasound CT MR*. 1998;19(2):175-89. doi:10.1016/S0887-2171(98)90059-2
24. Pantongrag-Brown L, Krebs TL, Daly BD, Wong-You-Cheong JJ, Beiser C, Krause B, et al. Frequency of abdominal CT findings in AIDS patients with *M. avium* complex bacteraemia. *Clin Radiol*. 1998;53(11):816-9. doi:10.1016/S0009-9260(98)80192-X
25. Shakhgildian V, Kravchenko AV, Parkhomenko IUG, Tishkevich OA, Serova VV, Gruzdev BM. Liver involvement in secondary infections in HIV-infected patients. *Ter Arkh*. 2002;74(11):40-3.
26. Koh DM, Burn PR, Mathews G, Nelson M, Healy JC. Abdominal computed tomographic findings of *Mycobacterium tuberculosis* and *Mycobacterium avium* intracellulare infection in HIV seropositive patients. *Can Assoc Radiol J*. 2003;54(1):45-50.