



Research Article

ISSN : 2277-3657  
CODEN(USA) : IJPRPM

## ***Effect of Black Raisins (*Vitis vinifera*) on Aluminum Chloride Induced Alzheimer's Disease in Male Albino Rat***

**R. M. Aljarari\*, A. E. Bawazir**

*Department of Biology, Faculty of Science, Jeddah University, Jeddah, Saudi Arabia.*

*\* E-mail: rmaljarary @ uj.edu.sa*

### **ABSTRACT**

Alzheimer's disease (AD) is one of the most common dementia causes especially in elders. Black raisins (*Vitis vinifera*) have memory-enhancing effects. This study was designed to investigate the effect of oral administration of black raisins (*V. vinifera*) on aluminum-chloride ( $AlCl_3$ ) induced AD in male albino rats. Forty adult male Albino rats were equally and randomly divided into five groups, 8 rats in each. The rats of the first group received a vehicle and served as controls. The animals of the second group received raisin (5 g per rat/day) orally for 8 weeks. The rats in the third group were treated with  $AlCl_3$  (model of AD) (100 mg/kg BW/day) for 8 weeks. The animals of the fourth group were treated with  $AlCl_3$  (100 mg/kg BW/day) and raisin. The animals of the fifth group received rivastigmine (0.3 mg/kg BW/day) and  $AlCl_3$  (100 mg/kg BW/day) orally for 8 weeks. After eight weeks, the behavioral test (maze learning test) was performed on all rats to assess learning and memory. Moreover, acetylcholinesterase (AChE) activity, some neurotransmitter levels [dopamine (DA), norepinephrine (NE), gamma-aminobutyric acid (GABA)], and oxidative stress [reduced glutathione (GSH), superoxide dismutase (SOD), oxidase glutathione (GSSG), and lipid peroxidation (LPO)] were estimated in the cortex and hippocampus homogenate. The histopathological studies were also made in the hippocampus area. The results showed that aluminum exposure significantly decreased the learning and memory in the maze-learning test as revealed by increase in elapsed time and error number in the maze. Significant increase of cortex and hippocampus homogenate levels of AChE and LPO, but a significant decrease in DA, NE, GABA, GSH, GSSG, and SOD were observed in rats subjected to  $AlCl_3$ . Histopathological evaluations of hippocampus sections of rats treated with  $AlCl_3$  showed severe alterations including the increase of degenerated cells with structural damage. The treatment of rats with raisin or rivastigmine for 8 weeks showed a pronounced attenuation on the damage caused by  $AlCl_3$  associated with the improvement of behavioral, biochemical, and histopathological alterations. This study suggested that chronic oral administration of black raisin had neuroprotective effects and improved learning and memory in AD animal models. These actions were done due to the antioxidant constituents of raisin.

**Key words:** Alzheimer's disease, Aluminum chloride, Maze learning test, acetylcholine esterase, Black raisin (*Vitis vinifera*), Neurotransmitters, Oxidative stress markers, Rats.

### **INTRODUCTION**

Neurodegenerative diseases are progressive central nervous system (CNS) disorders characterized by cognitive, motor, and/or behavioral dysfunctions. According to the World Health Organization (WHO), by 2040, neurodegenerative diseases will surpass the cancer mortality rate in industrialized countries. [1] AD affects one in nine people > 65 years old. Worldwide, AD patients' number was 36 million in 2010 and will triple by 2050. [2] AD is probably the result of many factors such as age, genetics, sex, trauma to the head, environmental exposure, cerebrovascular risk factors, oxidative stress, and infectious agents. [3] Many brain sites are affected by AD such as the entorhinal cortex, hippocampus, frontoparietal cortex, temporal cortex, and subcortical nuclei. [4] Dysfunction of neurotransmitters in brain including serotonin (5-HT), acetylcholine (ACh), dopamine (DA), norepinephrine (NE), glutamate (Glu), and gamma-aminobutyric acid (GABA) is also related to AD pathological findings. [5] The actions of excitatory and inhibitory neurotransmitters in learning, memory, and cognition are disturbed by AD. [6]

Aluminum (Al) is the third most plentiful element and the most common metal in earth's coating. Humans are exposed to Al via food, cooking utensils, antacids, deodorants, infant formulae, occupational exposure in the

gun, aerospace, vehicles as cars, and defense-related factors. It has been estimated that the dietary intake of Al ranges from 3 to 30 mg/day. [7] Al accumulates mainly in the bone, liver, testes, kidneys, and brain. Studies revealed that the brain consists of low Al levels and its uptake by the brain is slower than other organs, but once gained access into the brain, Al distributes into various brain regions. [8] Previous studies have shown that Al accumulation in the brain is associated with the pathophysiology of neurodegenerative disorders including AD, Guam-Parkinson's dementia, amyotrophic lateral sclerosis, etc. [9]

Intake of polyphenols in diets is a promising nutraceutical or pharmaceutical substance to inhibit AD progression. [10] Raisins (dried grapes, *Vitisvinifera*) are favorite food since 1490 B.C. due to their nutritive value. [11] Raisins contain a variety of flavonoids and antioxidants such as anthocyanin, phenolic acid, tannin, vitamins, pro-anthocyanidin and a high amount of phenolics as well as non-flavonoid compounds as hydroxycinnamic acids and hydroxybenzoic acids. [12] Raisin has some of the highest polyphenolic content and antioxidant oxygen radical absorbance capacity (ORAC) levels compared to the other fruits. [13] Moreover, raisin is a good source of boron, a trace element that is necessary for brain function, such as hand-eye coordination, memory, and attention. [14]

Relatively few studies have examined the effect of black raisins (*V. vinifera*) on AD. Therefore, this study aimed to search the beneficial effects of oral administration of raisins for 8 weeks on behavior, as well as hippocampus and cortex levels of some neurotransmitters and oxidation stress markers in  $AlCl_3$ -induced AD in rats. In addition, histopathological examination of the hippocampus area was made.

## MATERIALS AND METHODS

### Materials

#### Animals

Forty adult male Albino Wistar rats weighting 170-210 g were used in the study. The rats were purchased from the Experimental Animal Unit of Faculty of Pharmacy, King Abdulaziz University, Jeddah, Saudi Arabia. All experiments were approved and made regarding the rules of the Animal Care and Use Committee of King Abdul-Aziz University, Faculty of Pharmacy, Jeddah, Saudi Arabia (1161439). The rats were adapted to the laboratory conditions for one week before the beginning of the experiments. They were housed in clean plastic cages and kept in controlled laboratory status of temperature ( $20\pm 1^\circ C$ ), humidity (65%), and 12 h light: dark cycle. The animals had free tap water and food *ad libitum* on a normal commercial chow diet.

#### Chemicals

$AlCl_3$  (Techno Pharmchem, Haryana, India) was supplied as a white powder. Rivastigmine, Exelon, 1.5 mg, obtained from Novartis Company (Basel, Switzerland). Sodium chloride (NaCl) and sodium hydroxide (NaOH) were obtained from Panreac (Barcelona, Spain). Potassium chloride (KCl), disodium phosphate ( $Na_2HPO_4$ ), potassium dihydrogen phosphate ( $KH_2PO_4$ ), and formaldehyde were obtained from Riedel-de Haën (Seelze, Germany).

#### Black raisins

Black raisins (*V. vinifera*) were obtained from a local market in Jeddah, Saudi Arabia. Black raisins had been imported from Afghanistan. They were purchased in closed packages.

#### Experimental Design

The rats were randomly sorted into five experimental groups (8 rats each). **Group 1 (control group):** The rats of this group were orally given 0.9 ml of saline solution (0.9% NaCl) (vehicle), daily for eight weeks. **Group 2 (Raisin group):** The rats of this group were allowed free access to black raisins at the dose of 5 g per day for each rat for eight weeks. [15] **Group 3 ( $AlCl_3$  group):** The rats were orally given 0.9 ml that contained 100 mg/kg BW of  $AlCl_3$  daily for eight weeks to induce AD. [16] **Group 4 (Raisin +  $AlCl_3$  group):** The rats were allowed to have free access to black raisins at the same dose as given to group 2 and  $AlCl_3$  after 1 hour at the same dose as given to group 3 daily for eight weeks. **Group 5 (Rivastigmine +  $AlCl_3$  group):** The rats were orally supplemented with rivastigmine at the dose of 0.9 ml that contained 0.3 mg/kg BW [17] and  $AlCl_3$  after 1 hour at the same dose as given to group 3 daily for eight weeks.

#### Behavior Study (Maze learning test)

Maze learning test is a reliable method of studying trial and error learning. The rats were deprived of food for 23 h before the initiation of the experiments. The rats were then given their daily amount of food as a reward at the end of the maze. The hungry rats were given one trial per day for five successive days. The elapsed time to reach the food (minutes) and the number of errors (passage in blind alleys) were recorded. [18]

### Tissue preparation

After the behavioral test, the rats were euthanized by gentle decapitation following the rules of King Abdul-Aziz University. After the dissection of rats, their brains were removed and washed with saline and divided into two halves in a sagittal plane. One half was fixed in 10% formalin for histopathological examination. The hippocampus and cortex of the other half were dissected out and immediately frozen in  $-80^{\circ}\text{C}$  for tissues homogenate preparation. The homogenate was centrifuged for 15 min at 3000 rpm and  $4^{\circ}\text{C}$ . After that, the supernatant was separated, aliquoted, and stored in the Eppendorf tube at  $-80^{\circ}\text{C}$  for the biochemical assay.

### Biochemical assay

ELISA kits were used for the measurement of hippocampus and cortex tissues homogenate for Acetylcholinesterase (AChE) (Cat. # MBS038896), Dopamine (DA) (Catalog Number # MBS7214676), Norepinephrine (NE) (Catalog # MBS269993), and Gamma-aminobutyric acid (GABA) (Catalog Number # MBS740443), Superoxide Dismutase (SOD) (Catalog # MBS266897), Lipid Peroxide (LPO) (Catalog # MBS2515688) while, Fluorometric Assay kits were used to measure Reduced Glutathione (GSH) and Oxidized Glutathione (GSSG) (Catalog Number # MBS841503). All kits were purchased from My BioSource (San Diego, USA).

### Histopathological studies

After the fixation of brain tissues in formalin saline (10%) for 24 hours, the brain tissues were subjected to serial dilution of alcohol for dehydration. The brain tissues were embedded in paraffin, sectioned into  $3\ \mu\text{m}$  thick sections, and stained in hematoxylin and eosin (H and E) to be examined by a light microscope.

### Statistical analysis

The statistical analysis was done by Statistical Package for Social Science (SPSS, version 25) (SPSS Inc., Chicago, IL, USA). The values were expressed as mean  $\pm$  standard error. The changes between different experimental groups were made using one-way ANOVA (Tukey test).  $P$ -value  $<0.05$  was recognized as significant.

## RESULTS:

### Behavior study (Maze learning test)

On the 1<sup>st</sup>, 2<sup>nd</sup>, 3<sup>rd</sup>, 4<sup>th</sup>, and 5<sup>th</sup> days, the duration of elapsed time in the maze was significantly prolonged in the  $\text{AlCl}_3$  group compared to the control, (Raisin +  $\text{AlCl}_3$ ), and (Rivastigmine +  $\text{AlCl}_3$ ) groups ( $P < 0.05$ ) (Figure 1).

on the 1<sup>st</sup>, 2<sup>nd</sup>, 3<sup>rd</sup>, 4<sup>th</sup>, and 5<sup>th</sup> days, the number of errors in the maze significantly decreased in the control, (Raisin +  $\text{AlCl}_3$ ) and (Rivastigmine +  $\text{AlCl}_3$ ) groups compared to  $\text{AlCl}_3$  group ( $P < 0.05$ ) (Figure 2).

### Acetylcholinesterase and Some Neurotransmitter levels in cortex and hippocampus homogenate

In the cortex and hippocampus homogenate of the  $\text{AlCl}_3$  group, the levels of AChE were significantly increased while the levels of DA, NE, and GABA were significantly decreased compared to the control group ( $P < 0.05$ ). In the evaluation of the cortex and hippocampus homogenate, it was observed that (Raisin +  $\text{AlCl}_3$ ) and (rivastigmine +  $\text{AlCl}_3$ ) groups AChE levels were significantly decreased while, DA, NE, and GABA levels were significantly increased compared to the  $\text{AlCl}_3$  group ( $P < 0.05$ ) (Table 1).

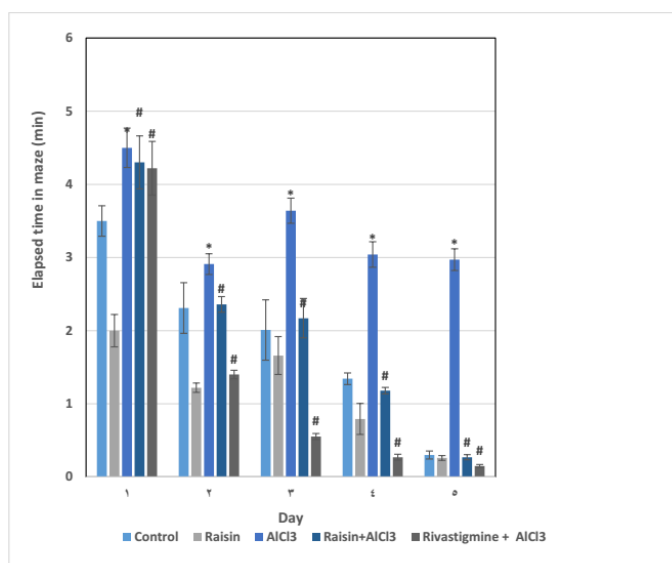
### Oxidative stress markers levels in cortex and hippocampus homogenate

The levels of GSH, GSSG, and SOD in the cortex and hippocampus homogenate significantly decreased while LPO levels were significantly increased in  $\text{AlCl}_3$  group than in the control group ( $P < 0.05$ ).  $\text{AlCl}_3$ -treated rats with Raisin and rivastigmine led to a significant increase in cortex and hippocampus GSH, GSSG, and SOD levels and a significant decrease in LPO in (Raisin +  $\text{AlCl}_3$ ) and (rivastigmine +  $\text{AlCl}_3$ ) groups compared to  $\text{AlCl}_3$  group ( $P < 0.05$ ) (Table 2).

### Results of histopathological studies

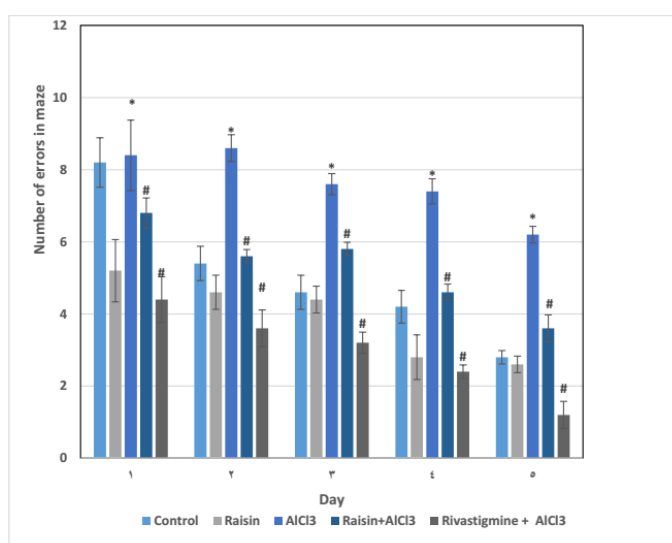
The hippocampus sections in Cornu Ammonis (CA1) were formed of three layers: polymorphic (POL), pyramidal (PYR), and molecular (MOL). Moreover, the dentate gyrus (DG) was formed of three layers: molecular (MOL), granular (GRA), and polymorphic (POL). The hippocampus sections in CA1 of the control and raisin extract-treated rats showed the normal pyramidal cells with rounded vesicular nuclei. Furthermore, the hippocampus sections in dentate gyrus (DG) of the control and raisin extract-treated rats revealed normal granular cells with vesicular nuclei and an increase in vasculature in raisin extract-treated group. After eight weeks of treatment with  $\text{AlCl}_3$ , the treated rats revealed an abnormal morphology in CA1 and DG of the hippocampus characterized by degenerated shrunken cells with darkly stained nuclei. In rats treated with (Raisin +  $\text{AlCl}_3$ ) and (rivastigmine +  $\text{AlCl}_3$ ), the hippocampus sections in CA1 and DG showed reduced degenerated

cells. In addition, the hippocampus cells in CA1 and DG showed slight changes compared to the cell structure of only AlCl<sub>3</sub>-treated rats (Figure 3).



**Figure 1.** Effects of black raisin and rivastigmine on the time taken to find the food in the learning maze by Alzheimer’s disease-induced rats

The values were expressed as mean±SE. \*P<0.05 compared with control. #P<0. 05 compared with Al



**Figure 2.** Effects of black raisin and rivastigmine on the number of errors in the learning maze by Alzheimer’s disease-induced rats

The values were expressed as mean±SE. \*P<0.05 compared with control #P<0.05 compared with Al

**Table 1.** Effects of black raisin and rivastigmine on cortex and hippocampus homogenate levels of acetylcholinesterase and some neurotransmitters in Alzheimer’s disease-induced rats

		Control	Raisin	AlCl <sub>3</sub>	Raisin+ AlCl <sub>3</sub>	Rivastigmine + AlCl <sub>3</sub>
<b>AchE</b> <b>(U/mg)</b>	Cortex	0.65±0.0821	0.5117±0.0414	1.3567±0.0761 <sup>a</sup>	0.71±0.0604 <sup>b</sup>	0.7283±0.0624 <sup>b</sup>
	Hip	1.79±0.1099	1.9783±0.0871	2.6883±0.1272 <sup>a</sup>	1.8317±0.0562 <sup>b</sup>	2.025±0.0615 <sup>b</sup>
<b>DA</b> <b>(pg/mg)</b>	Cortex	3.625±0.2869	3.9033±0.3139	0.4817±0.1311 <sup>a</sup>	3.0883±0.1401 <sup>b</sup>	3.455±0.2067 <sup>b</sup>
	Hip	4.2±0.4227	4.6483±0.2762	0.8083±0.1087 <sup>a</sup>	3.4017±0.2832 <sup>b</sup>	4.0667±0.249 <sup>b</sup>
<b>NE</b>	Cortex	4.5867±0.3553	4.5267±0.2601	1.0267±0.3371 <sup>a</sup>	3.3983±0.3493 <sup>b</sup>	5.8333±0.3566 <sup>b</sup>

(pg/mg)	Hip	5±0.4017	4.7167±0.4012	1.7483±0.2893 <sup>a</sup>	4.5883±0.449 <sup>b</sup>	6.7033±0.2939 <sup>b</sup>
<b>GABA</b>	Cortex	0.2767±0.0113	0.3517±0.0294	0.0738±0.0144 <sup>a</sup>	0.2783±0.0172 <sup>b</sup>	0.465±0.0184 <sup>b</sup>
(µmol/mg)	Hip	0.4383±0.0402	0.4867±0.0399	0.0985±0.0142 <sup>a</sup>	0.38±0.0213 <sup>b</sup>	0.7067±0.0226 <sup>b</sup>

The values were expressed as means ±S.E of eight animals. P<0.05 (significant)

a = Significant difference compared to the normal control group.

b = Significant difference compared to the AlCl<sub>3</sub> group.

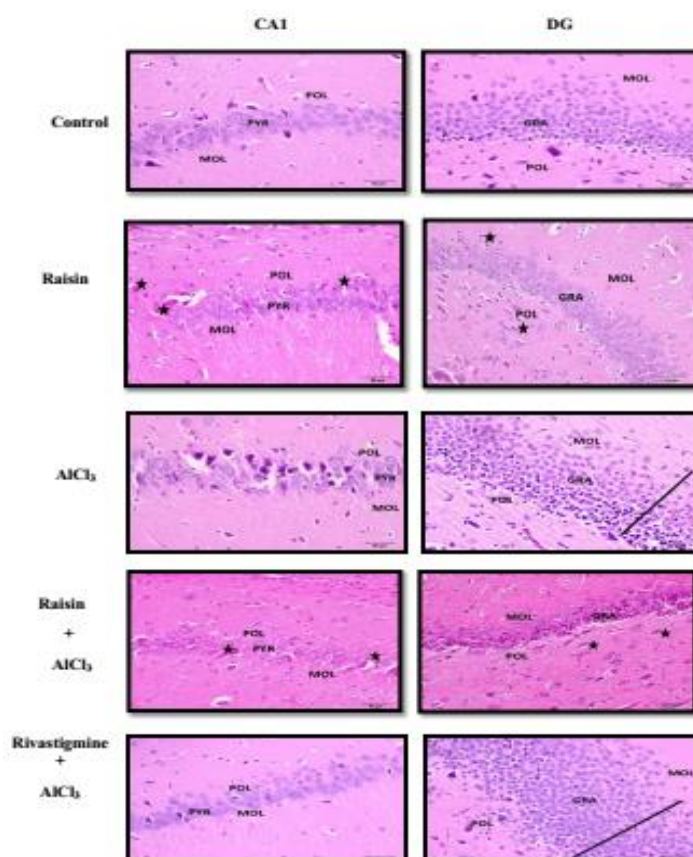
**Table 2.** Protective effects of black raisin and rivastigmine on the cortex and hippocampus homogenate levels of oxidative parameters in Alzheimer's disease-induced rats

		Control	Raisin	AlCl <sub>3</sub>	Raisin+ AlCl <sub>3</sub>	Rivastigmine +AlCl <sub>3</sub>
<b>GSH</b> (µmol/mg)	Cortex	4.255±0.3425	4.7417±0.3343	0.8783±0.1126 <sup>a</sup>	2.94±0.1414 <sup>b</sup>	4.2833±0.3722 <sup>b</sup>
	Hip	4.42±0.4694	4.8333±0.3117	0.7167±0.1126 <sup>a</sup>	3.0683±0.1219 <sup>b</sup>	5.725±0.2722 <sup>b</sup>
<b>GSSG</b> (µmol/mg)	Cortex	4.635±0.3059	4.4417±0.3814	1.0417±0.1551 <sup>a</sup>	3.0717±0.2526 <sup>a,b</sup>	4.9717±0.404 <sup>b</sup>
	Hip	4.99±0.2762	4.7333±0.3783	1.2867±0.1991 <sup>a</sup>	2.9617±0.1436 <sup>a,b</sup>	5.455±0.2796 <sup>b</sup>
<b>SOD</b> (µmol/mg)	Cortex	85.8333±7.0067	84.6667±6.1409	20.45±2.7835 <sup>a</sup>	56.3333±4.3944 <sup>a,b</sup>	91±5.2409 <sup>b</sup>
	Hip	86±6.4057	87.3333±6.8783	16.2333±2.3638 <sup>a</sup>	50.4±3.0681 <sup>a,b</sup>	79±6.2794 <sup>b</sup>
<b>LPO</b> (µmol/mg)	Cortex	0.735±0.0703	0.59±0.0386	9.2±0.0394 <sup>a</sup>	3.1483±0.0787 <sup>b</sup>	0.2483±0.0904 <sup>b</sup>
	Hip	1.0917±0.0703	1.26±0.0386	36±0.0394 <sup>a</sup>	14.3483±0.0787 <sup>a,b</sup>	0.7383±0.0904 <sup>b</sup>

The values were expressed as means ±S.E of eight animals. P<0.05 (significant)

a = Significant difference compared to the normal control group.

b = Significant difference compared to the AlCl<sub>3</sub> group.



**Figure 3.** H&E staining (magnification 400×). The pyramidal cells in CA1 have large vesicular nuclei in the control, raisin-treated, and rivastigmine-treated groups, but in the Al group, they have irregular forms. In addition, there is an increase in vasculature (stars) in the raisin-treated groups. The granular cells in DG have vesicular nuclei in control, raisin-treated, and rivastigmine-treated groups, but in the Al group, they have irregular forms. Moreover, there is an increase in dilated capillaries (stars) in raisin-treated groups in DG. Treatment by raisin improved the morphological changes induced by AlCl<sub>3</sub>.

## DISCUSSION

The results of this study revealed that the intake of  $\text{AlCl}_3$  (100 mg/kg BW orally daily) for eight weeks by rats (AD model) led to the impairment of learning and memory abilities compared to the normal rats that manifested the increase in elapsed time and increase in the number of errors in the maze learning test to get food. These results indicated that  $\text{AlCl}_3$  exposure resulted in the impairment of locomotor activity and exploratory behavior (maze learning test) of the rats and a decrease in spatial memory. These results agreed with the previous study, which reported that Al exposure had a neurodegeneration effect that led to learning deficits. The rats injected with  $\text{AlCl}_3$  intraperitoneally for 60 days (100 mg/kg BW) led to decreased memory in the Morris Water Task (MWT) and a passive avoidance test that assessed the spatial memory. However, the oral administration of raisin 6 g per rat for 60 days during Al exposure led to a significant increase in spatial memory. [15] Yassin *et al.* [19] reported that the rats treated with  $\text{AlCl}_3$  revealed an increase in the time length spent by rats to get the food in the T-maze experiment. These findings supported other investigations that demonstrated that Al can induce disorder in cholinergic neurotransmission leading to memory alterations. [20]

The results of this study revealed that, in contrast to  $\text{AlCl}_3$ -treated rats, the learning and memory abilities were significantly improved in AD rats treated with raisin (5 g for each rat, orally) for 8 weeks. This result showed that raisin can reduce the harmful effects of Al on learning and memory. Ghorbanian *et al.* [21] reported that daily consumption of 6 g of raisins for 90 days enhanced the spatial learning and memory in aged rats (20 months). In addition, they reported that morphometric alterations occurred in the corpus callosum and hippocampus in old rats received raisins daily, which provided further evidence for the neuroprotective effects of raisin on the brain.

Rivastigmine was used as a standardized drug as it is the only proven pharmacological therapy for symptomatic AD treatment. The treatment of AD rats with rivastigmine as a therapeutic and/or protective agent led to a significant increase in the locomotor activity levels in the cages and a decrease in the number of errors in the maze compared to the AD-induced groups of rats. Rivastigmine improved the behavioral impairment, increased the antioxidant enzymes in the brain, and ameliorated the mitochondrial enzyme activity-induced neurotoxicity. [22]

Cognitive dysfunction was due to the decline of cholinergic transmitters' activities. The results of the present study demonstrated that the oral administration of  $\text{AlCl}_3$  in the AD rat model produced a significant increase in AchE activities of the cerebral cortex and hippocampus homogenate accompanied by a significant decrease in DA, NE, and GABA contents in comparison to the control group. Such results of increased AchE activities coincided with the findings of other studies. [19] It has been demonstrated that the increase in AchE activity after Al exposure was due to the allosteric reaction between Al and peripheral anionic location of enzyme molecule resulting in changes of the secondary structure and enzyme activity. [23]

Ibraheem and his colleagues [24] reported a significant decrease in 5-HT and DA in contrast to the significantly elevated levels of NE in both cortex and hippocampus homogenate in rats exposed to  $\text{AlCl}_3$  orally for 90 days.  $\text{AlCl}_3$  inhibition of DA, observed herein might be explained partly by the effects of  $\text{AlCl}_3$  on the sensitivity status of 5-HT<sub>2C</sub> receptors in rats. [25] The suppression of dopaminergic transmission in CNS might play an important role in  $\text{AlCl}_3$ -induced neurotoxicity. [26] Ibraheem *et al.* [24] explained the elevation in cerebral NE in  $\text{AlCl}_3$ -exposed rats may be due to the stress, caused by the metal that led to the activation of its synthetic pathway, particularly the hydroxylation step involved in the conversion of DA to NE. [27] Actually, the imbalance in brain bipterins caused the deficit of various neurotransmitters such as 5-HT, DA, and NE. [24] Furthermore, the changes of brain neurotransmitters (DA and NE) in  $\text{AlCl}_3$ -treated rats may lead to formation of more  $\text{O}_2$  and  $\text{H}_2\text{O}_2$  in the hippocampus and cortex leading to neurodegenerative diseases and Lewy bodies aggregations. [28] Furthermore, the increased iron species concentration between Al-induced rats enhanced DA oxidation producing DA quinones that reacted with cysteine residues of functional proteins as GSH, suppressing their activity and detoxification action. [29].

Regarding inhibitory neurotransmitters,  $\text{AlCl}_3$  induced reduction in the cerebral cortex and hippocampus GABA contents, observed herein, was similar to that described by [30] who demonstrated that  $\text{AlCl}_3$  selectively modulated GABA receptors function leading to widespread changes in inhibitory circuits that contributed to neuropathology. [31] The decrease in GABA level might be due to the increase in its catabolism through enzymatic activities and selective loss of GABAergic neurons due to exposure to  $\text{AlCl}_3$ . [32] Meanwhile, [33] reported that Al-exposed rats had a lower glutamate level and a higher GABA level.

The results of the present study showed that the oral administration of raisin for 8 weeks led to a significant decrease in AchE contents of the cerebral cortex and hippocampus homogenate accompanied by a significant

increase in DA, NE, and GABA contents in comparison to AlCl<sub>3</sub> group. Ma *et al.* [34] reported that *Vitis vinifera L. flavones* (VTF) inhibited AchE activity and improved acetylcholine transferase (ChAT) activity that indirectly led to an increase in Ach level, which proved the protective effect of VTF on AD due to the enhancement of cholinergic nerve functions. Raisin extracts showed *in vitro* suppression of monoamine oxidase (MAO) activity that destructed NE. Two aromatic  $\beta$ -carbolines (i.e., norharman and harman) were extracted from raisins that were responsible for MAO inhibition shown in raisins. [35]

Considering the results of this study, it has been demonstrated that the treatment of AD-rats with rivastigmine significantly decreased cortex and hippocampus homogenate levels of AchE activity and increased DA, NE, and GABA levels. These results are in agreement with others who demonstrated that rivastigmine intake increased the concentration of Ach and inhibited AchE activities in the brain. [19] Rivastigmine is a carbamate-derived pseudo-irreversible cholinesterase inhibitor, which can inhibit both AchE and BuchE1. The glutamatergic system was modulated after AchE inhibition by rivastigmine. [36] Therefore, the mechanism by which rivastigmine can improve the cognition of these rats is related to its potential to increase Ach and decrease AchE activity as shown in the present study.

Experimental evidence has considered brain a sensitive organ because of its high rate of O<sub>2</sub> usage, high content of polyunsaturated fatty acids and iron, which lead to lipid peroxidation. [37] Free radicals have been drawn to the double bonds of unsaturated fatty acids. In addition, compared to other organs, brain tissues are poor in antioxidants. [38] Meanwhile, neurons naturally possess a high aerobic metabolism. These factors come together to make the nervous system liable to the oxidative damage. In this study, the rats' intake of AlCl<sub>3</sub> led to a significant decrease in the cerebral cortex and hippocampus homogenates of antioxidant enzymes including GSH, GSSG, and SOD, as well as a significant increase in the oxidative stress marker such as LPO levels. GSH depletion increased signaling processes, leading to the death of the neurons and central excitabilities. [39] Deloncle *et al.*, 1999 [40] reported that AlCl<sub>3</sub> neurotoxicity is due to the increase in lipid peroxidation and damage to the blood-brain barrier. SOD catalyzed the rapid removal of superoxide radicals generating hydrogen peroxide (H<sub>2</sub>O<sub>2</sub>), which was eliminated by catalase (CAT). [41] The observed decrease in those antioxidant enzymes activities after AlCl<sub>3</sub> administration compared to the control group was in accordance with previous reports by others. [42] Mahdy *et al.* [43] reported that AlCl<sub>3</sub>-induced AD-rats showed significant increases in serum levels of nitric oxide (NO) and MDA as well as significant decreases in actions of SOD and total antioxidant capacity (TAC). Lakshmi *et al.* [12] reported that chronic Al intake led to oxidative stress, as proved by a marked increase in MDA levels and decreased endogenous antioxidants i.e. CAT, glutathione reductase (GR), and GSH. The primary effects of Al on brain functions were mediated via destruction of cell membranes. [44] Al changed calcium flux and homeostasis and facilitated the peroxidation of membrane lipids. [45] The decreased activity of antioxidant enzymes resulted from oxidative changes in genes that controlled these enzymes' formation and action. [12]

Raisin contains polyphenol and phenolic acid compounds, which have antioxidant properties. The role of natural polyphenols in the body is to remove free radicals, activate antioxidant enzymes, chelate metal catalysts, decrease  $\alpha$ -tocopherol radicals, and suppress oxidases. [46] In this study, the treatment of AD-rats with raisin for 8 weeks led to a significant increase in the cerebral cortex and hippocampus homogenates of GSH, GSSG, and SOD as well as a significant decrease in LPO levels. In this respect, Gol *et al.* [15] reported that raisin treatment during Al exposure showed a significant decrease of LPO and an increase in ferric reducing/antioxidant power (FRAP) compared to the Al-treated group. This could be mainly due to the antioxidant and free radical scavenging properties of the raisins. [47] Ghorbanian *et al.* [21] reported that the serum levels of FRAP as the marker of evaluation of the antioxidant status significantly increased, but the average concentration of LPO or MDA significantly reduced in aged rats receiving raisins for 90 days compared to the control rats. Lakshmi *et al.* [12] reported that supplement with *V. vinifera* extract (400 mg/kg) to Al treated rats led to a significant decline in the MDA levels and increase in the level of antioxidant enzymes including CAT and GR. Moreover, *V. vinifera* extract contained many compounds like flavonoids, anthocyanins, sugars, proanthocyanins, tannin, mineral salts, resveratrol, organic acids, and vitamins. These substances have been proven to act as antioxidants in oxidative stress models. [12] Previous studies reported that 5-hydroxymethylfurfural (5-HMF) amount in dry grape products, i.e. currant, raisin, and cooked grapes must be taken into consideration. [47] In a study made on human neuroblastoma cell line, SH-SY5Y, 5-HMF protected nerve cells against sodium azide-induced degradation via conserving the cytoskeleton and declining the intracellular A $\beta$ , and it was suggested that HMF had an important role in treating neurodegenerative diseases. [48]

Treatment of AD-rat models with rivastigmine as a therapeutic or protective agent led to an improvement in the oxidative stress status, as represented in this study by a significant increase in cerebral cortex and hippocampus homogenates of GSH, GSSG, and SOD, as well as a significant decrease in LPO levels. Rivastigmine may act through decreasing oxidative stress and restoring antioxidant capacity. [49]

A neuropathological study of brain tissue of AD-induced rats revealed neuronal degeneration and edema. Abnormal morphology in CA1 and DG of hippocampus was characterized by degenerated shrunken cells with darkly stained nuclei. However, AI caused an impairment in the hippocampus due to the destruction of neurons and gliosis, and this may affect many enzymes responsible for synthesis and destruction of various neurotransmitters. [12] Moreover, AI can pass the blood-brain barrier, get accumulated in the brain and hippocampus, and produce neurotoxic actions. [15] However, AD brains exhibited chronic inflammation and oxidative damage [50] that plays a significant role in the onset and progression of AD.

In AD rats treated with raisin and rivastigmine, hippocampus sections in CA1 and DG showed reduced degenerated cells. In addition, the hippocampus cells in CA1 and DG showed slight changes in comparison to the cell structure of rats treated with  $AlCl_3$  alone. The hippocampus sections of CA1 in control, and raisin and (raisin +  $AlCl_3$ ) treated rats revealed normal pyramidal cells with vesicular nuclei. Furthermore, the hippocampus sections of DG in control, raisin extract and (raisin +  $AlCl_3$ ) treated rats showed normal granular cells with vesicular nuclei. Also, there was an increase in the dilated capillaries in raisin extract and (raisin +  $AlCl_3$ ) treated groups due to the increase of NO. Decreasing changes in the shape of neurons in the hippocampus, as well as the decline of abnormal variations and irregularities in the arrangement of neurons along with the increased number of pyramidal and granular neurons in raisin rats, emphasized on the neuroprotective role of foods rich in antioxidants in the brain structure and function. [21] A study on aged rats showed that the lateral ventricle diameter of rats in the raisin group was found to be smaller with less death rate and degeneration compared to the control rats. [21]

The photomicrograph of brain tissue sections of AD-induced rats' given rivastigmine revealed no histopathological alterations in hippocampus. Coleman *et al.* [51] reported that treatment with rivastigmine in a primary cell culture model could maintain neurons, neuronal morphology, and synaptic markers that are necessary for a normal neuronal action. Moreover, Bihaqi *et al.* [52] demonstrated the normal histological appearance of the brain cells treated with rivastigmine tartrate. These authors stated that rivastigmine could reverse the histopathological alterations of the brain caused by  $AlCl_3$ .

## CONCLUSION

From this study, it could be concluded that the raisin had a neuroprotective effect on rats with AD. It prevented LPO arising, increased GSH, GSSG, and SOD levels in the brain, and improved memory and learning in the AD rat models. Moreover, it increased the formation of neurotransmitters including DA, NE, and GABA in the brain and decreased AchE enzyme activity that destructs Ach, as an excitatory neurotransmitter in the brain. It could ameliorate the neurodegenerative characteristics of AD. The findings of the present study suggested the therapeutic potential of black raisins in neurodegenerative diseases such as Alzheimer's disease. Further clinical trials on humans are required to determine the efficacy of black raisin or one or more of its constituents on neurodegenerative disorders.

## REFERENCES

1. Ip PS, Tsim KW, Chan K, Bauer R. Application of complementary and alternative medicine on neurodegenerative disorders: current status and future prospects. *Evidence-Based Complementary and Alternative Medicine*. 2012;2012.doi: 10.1155/2012/930908.
2. Huang Y, Mucke L. Alzheimer mechanisms and therapeutic strategies. *Cell*. 2012 Mar 16;148(6):1204-22.
3. Tramutola A, Lanzillotta C, Perluigi M, Butterfield DA. Oxidative stress, protein modification and Alzheimer disease. *Brain research bulletin*. 2017 Jul 1;133:88-96.
4. Reddy PH, McWeeney S. Mapping cellular transcriptosomes in autopsied Alzheimer's disease subjects and relevant animal models. *Neurobiology of Aging*. 2006 Aug 1;27(8):1060-77.
5. Chalermpananupap T, Kinkead B, Hu WT, Kummer MP, Hammerschmidt T, Heneka MT, Weinschenker D, Levey AI. Targeting norepinephrine in mild cognitive impairment and Alzheimer's disease. *Alzheimer's research & therapy*. 2013 Apr 1;5(2):21.



6. Chen KH, Reese EA, Kim HW, Rapoport SI, Rao JS. Disturbed neurotransmitter transporter expression in Alzheimer disease brain. *Journal of Alzheimer's disease: JAD*. 2011 Jan 1;26(4):755.
7. Bharathi VP, Govindaraju M, Palanisamy AP, Sambamurti K, Rao KS. Molecular toxicity of aluminium in relation to neurodegeneration. *Indian J Med Res*. 2008 Oct 1;128(4):545-6.
8. Yokel RA, Rhineheimer SS, Sharma P, Elmore D, McNamara PJ. Entry, half-life, and desferrioxamine-accelerated clearance of brain aluminum after a single <sup>26</sup>Al exposure. *Toxicological Sciences*. 2001 Nov 1;64(1):77-82.
9. Garruto RM, Fukatsu R, Yanagihara R, Gajdusek DC, Hook G, Fiori CE. Imaging of calcium and aluminum in neurofibrillary tangle-bearing neurons in parkinsonism-dementia of Guam. *Proceedings of the National Academy of Sciences*. 1984 Mar 1;81(6):1875-9.
10. Vauzour D. Effect of flavonoids on learning, memory and neurocognitive performance: relevance and potential implications for Alzheimer's disease pathophysiology. *Journal of the Science of Food and Agriculture*. 2014 Apr;94(6):1042-56.
11. Fang YL, Zhang A, Wang H, Li H, Zhang ZW, Chen SX, Luan LY. Health risk assessment of trace elements in Chinese raisins produced in Xinjiang province. *Food Control*. 2010 May 1;21(5):732-9.
12. Lakshmi BV, Sudhakar M, Anisha M. Neuroprotective role of hydroalcoholic extract of *Vitis vinifera* against aluminium-induced oxidative stress in rat brain. *Neurotoxicology*. 2014 Mar 1;41:73-9.
13. Jeszka-Skowron M, Zgoła-Grzeškowiak A, Stanisiz E, Waśkiewicz A. Potential health benefits and quality of dried fruits: Goji fruits, cranberries and raisins. *Food chemistry*. 2017 Apr 15;221:228-36.
14. Nielsen FH. Biochemical and physiologic consequences of boron deprivation in humans. *Environmental health perspectives*. 1994 Nov;102(suppl 7):59-63.
15. Gol M, Ghorbanian D, Soltanpour N, Faraji J, Pourghasem M. Protective effect of raisin (currant) against spatial memory impairment and oxidative stress in Alzheimer disease model. *Nutritional neuroscience*. 2019 Feb 1;22(2):110-8.
16. Thenmozhi AJ, Raja TR, Janakiraman U, Manivasagam T. Neuroprotective effect of hesperidin on aluminium chloride induced Alzheimer's disease in Wistar rats. *Neurochemical research*. 2015 Apr 1;40(4):767-76.
17. Carageorgiou H, Sideris AC, Messari I, Liakou CI, Tsakiris S. The effects of rivastigmine plus selegiline on brain acetylcholinesterase, (Na<sup>+</sup>, K<sup>+</sup>)-, Mg<sup>2+</sup>-ATPase activities, antioxidant status, and learning performance of aged rats. *Neuropsychiatric disease and treatment*. 2008 Aug;4(4):687.
18. Staddon JE. *Adaptive behavior and learning*. Cambridge University Press; 2016 Mar 10.
19. Yassin N, El-Shenawy S, Mahdy KA, Gouda N, Marrie A, Farrag A, Ibrahim BM. Effect of *Boswellia serrata* on Alzheimer's disease induced in rats. *J Arab Soc Med Res*. 2013 Jan;8:1-1.
20. Kakad VD, Mohan M, Kasture VS, Kasture SB. Effect of *Vitis vinifera* on memory and behaviour mediated by monoamines. *Journal of Natural Remedies*. 2008 Jun 1;8(2):164-72.
21. Ghorbanian D, Gol M, Pourghasem M, Faraji J, Pourghasem K, Soltanpour N. Spatial Memory and Antioxidant Protective Effects of Raisin (Currant) in Aged Rats. *Preventive Nutrition and Food Science*. 2018 Sep;23(3):196.
22. Kumar P, Kumar A. Protective effect of rivastigmine against 3-nitropropionic acid-induced Huntington's disease like symptoms: possible behavioural, biochemical and cellular alterations. *European journal of pharmacology*. 2009 Aug 1;615(1-3):91-101.
23. Kaizer RR, Correa MC, Gris LR, Da Rosa CS, Bohrer D, Morsch VM, Schetinger MR. Effect of long-term exposure to aluminum on the acetylcholinesterase activity in the central nervous system and erythrocytes. *Neurochemical research*. 2008 Nov 1;33(11):2294-301.
24. Ibraheem, E. H. E., Moham, E. K. W., & Taher, M. A. Perturbation of brain neurotransmitters by aluminum in male rats and potential role of sage. *The Egyptian Journal of Experimental Biology (Zoology)*, 2011;7(2),249-259.
25. Brus R, Szkilnik R, Popieluch I, Kostrzewa RM, Mengel K. Effect of aluminium exposure on central serotonin and muscarine receptors reactivity in rats. *Medical Science Monitor*. 1997 Sep 1;3(5):BR631-6.
26. Zheng YX, Liang YX. The antagonistic effects of L-dopa and eserine on Al-induced neurobehavioral deficits in rats. *Biomedical and environmental sciences: BES*. 1998 Dec;11(4):321-30.
27. Siegel GJ. *Basic neurochemistry: molecular, cellular and medical aspects*. 1999.

28. Burke WJ, Li SW, Chung HD, Ruggiero DA, Kristal BS, Johnson EM, Lampe P, Kumar VB, Franko M, Williams EA, Zahm DS. Neurotoxicity of MAO metabolites of catecholamine neurotransmitters: role in neurodegenerative diseases. *Neurotoxicology*. 2004 Jan 1;25(1-2):101-15.
29. Xu Y, Stokes AH, Roskoski Jr R, Vrana KE. Dopamine, in the presence of tyrosinase, covalently modifies and inactivates tyrosine hydroxylase. *Journal of neuroscience research*. 1998 Dec 1;54(5):691-7.
30. Trombley PQ. Selective modulation of GABAA receptors by aluminum. *Journal of neurophysiology*. 1998 Aug 1;80(2):755-61.
31. Nayak P, Chatterjee AK. Differential responses of certain brain phosphoesterases to aluminium in dietary protein adequacy and inadequacy. *Food and chemical toxicology*. 2001 Jun 1;39(6):587-92.
32. Gonçalves PP, Silva VS. Does neurotransmission impairment accompany aluminium neurotoxicity?. *Journal of Inorganic Biochemistry*. 2007 Sep 1;101(9):1291-338.
33. Shuchang H, Qiao N, Piye N, Mingwei H, Xiaoshu S, Feng S, Sheng W, Opler M. Protective effects of *gastrodia elata* on aluminium-chloride-induced learning impairments and alterations of amino acid neurotransmitter release in adult rats. *Restorative neurology and neuroscience*. 2008 Jan 1;26(6):467-73.
34. Ma L, Xiao H, Wen J, Liu Z, He Y, Yuan F. Possible mechanism of *Vitis vinifera* L. flavones on neurotransmitters, synaptic transmission and related learning and memory in Alzheimer model rats. *Lipids in health and disease*. 2018 Dec;17(1):152.
35. Herraiz T. Identification and occurrence of  $\beta$ -carboline alkaloids in raisins and inhibition of monoamine oxidase (MAO). *Journal of agricultural and food chemistry*. 2007 Sep 21;55(21):8534-40.
36. Andin J, Enz A, Gentsch C, Marcusson J. Rivastigmine as a modulator of the neuronal glutamate transporter rEAAC1 mRNA expression. *Dementia and geriatric cognitive disorders*. 2005;19(1):18-23.
37. Halliwell B. Role of free radicals in the neurodegenerative diseases. *Drugs & aging*. 2001 Sep 1;18(9):685-716.
38. Gilgun-Sherki Y, Melamed E, Offen D. Oxidative stress induced-neurodegenerative diseases: the need for antioxidants that penetrate the blood brain barrier. *Neuropharmacology*. 2001 Jun 1;40(8):959-75.
39. Yoneyama M, Nishiyama N, Shuto M, Sugiyama C, Kawada K, Seko K, Nagashima R, Ogita K. In vivo depletion of endogenous glutathione facilitates trimethyltin-induced neuronal damage in the dentate gyrus of mice by enhancing oxidative stress. *Neurochemistry international*. 2008 Mar 1;52(4-5):761-9.
40. Deloncle R, Huguet F, Babin P, Fernandez B, Quellard N, Guillard O. Chronic administration of aluminium L-glutamate in young mature rats: effects on iron levels and lipid peroxidation in selected brain areas. *Toxicology letters*. 1999 Jan 11;104(1-2):65-73.
41. Fraga CG, Oteiza PI, Golub MS, Gershwin ME, Keen CL. Effects of aluminum on brain lipid peroxidation. *Toxicology Letters*. 1990 Apr 1;51(2):213-9.
42. Shati AA, Elsaid FG. Effects of water extracts of thyme (*Thymus vulgaris*) and ginger (*Zingiber officinale* Roscoe) on alcohol abuse. *Food and chemical toxicology*. 2009 Aug 1;47(8):1945-9.
43. Mahdy K, Shaker O, Wafay H, Nassar Y, Hassan H, Hussein A. Effect of some medicinal plant extracts on the oxidative stress status in Alzheimer's disease induced in rats. *Eur Rev Med Pharmacol Sci*. 2012 Jul 1;16(3):31-42.
44. Zatta P, Ibn-Lkhatay-Idrissi M, Zambenedetti P, Kilyen M, Kiss T. In vivo and in vitro effects of aluminum on the activity of mouse brain acetylcholinesterase. *Brain research bulletin*. 2002 Oct 15;59(1):41-5.
45. Bojarski L, Herms J, Kuznicki J. Calcium dysregulation in Alzheimer's disease. *Neurochemistry international*. 2008 Mar 1;52(4-5):621-33.
46. Oboh G, Rocha JB. Distribution and antioxidant activity of polyphenols in ripe and unripe tree pepper (*Capsicum pubescens*). *Journal of Food Biochemistry*. 2007 Aug;31(4):456-73.
47. Tagliazucchi D, Verzelloni E, Helal A, Conte A. Effect of grape variety on the evolution of sugars, hydroxymethylfurfural, polyphenols and antioxidant activity during grape must cooking. *International Journal of Food Science & Technology*. 2013 Apr;48(4):808-16.
48. Zhang RY, Piao JH, Chu J, Xu YL, Li L. Effects of hydroxymethyl-furfural on damages of nerve cell morphology and cyto-skeleton system induced by okadaic acid. *Tradit. Chin. Drug Res. Clin. Pharmacol*. 2008;19:417-21.

49. Shah S, Reichman WE. Treatment of Alzheimer's disease across the spectrum of severity. *Clinical interventions in aging*. 2006 Jun;1(2):131.
50. Praticò D, Uryu K, Sung S, Tang S, Trojanowski JQ, Lee VM. Aluminum modulates brain amyloidosis through oxidative stress in APP transgenic mice. *The FASEB Journal*. 2002 Jul;16(9):1138-40.
51. Coleman P, Federoff H, Kurlan R. A focus on the synapse for neuroprotection in Alzheimer disease and other dementias. *Neurology*. 2004 Oct 12;63(7):1155-62.
52. Bihaqi SW, Sharma M, Singh AP, Tiwari M. Neuroprotective role of *Convolvulus pluricaulis* on aluminium induced neurotoxicity in rat brain. *Journal of ethnopharmacology*. 2009 Jul 30;124(3):409-15.